

APEX RESECTION AND RETROGRADE FILLING AFTER ENUCLEATION OF RADICULAR CYST : A CASE REPORT

Teuku Ahmad Arbi ^{*}, Abdul Latif ^{}**

^{*}Lecture at PSKG Faculty of Medicine Syiah Kuala University

^{**} Lecturer at Department of Oral and Maxillofacial Surgery. Faculty of Dentistry Univ.
of Indonesia

ABSTRACT

Radicular cyst is a cyst at the apex of a non-vital tooth and is a sequel of pulp inflammation. The associated tooth is usually asymptomatic. Acute infectious episodes may cause pain. The lesion appears as a sharply circumscribed radiolucent lesion around the apex of the associated tooth. Several treatment options exist for such cysts. Many small cysts resolve with endodontic therapy ('root canal treatment') of the involved tooth. Those lesions should be monitored to ensure such resolution. Cysts that fail to resolve with such therapy should be surgically removed. This is often accompanied by an 'apex resection' of the tooth involved. This entails cutting off the end of the tooth and sealing, preventing the leakage of root canal filling. We present a case of Indonesian female, 24 years old with radicular cyst at second left maxillary incisor. The teeth was already performed root canal treatment, but the cyst did not decreased in size and the teeth was mobile. We decided to perform enucleation and apex resection of involved teeth. A mucoperiosteal flap over the cyst is raised & a window is opened in the bone to give adequate access. The cyst is carefully separated from its bony wall. The entire cyst is removed intact. The apex was cutting off 3 mm and MTA was place at the orifice of the root. The edge of bony cavity are smoothened off, free bleeding is controlled and cavity is irrigated to remove debris. Mucoperiosteal flap is replaced back and sutured in place. Three weeks after surgery, the patient has no complain on operation area, the tooth was not mobile and no pain. Radiographic evaluation shows that the operation area is healing successfully.

Keywords: Radicular cyst, enucleation, apex resection

INTRODUCTION

Radicular cysts are usually caused due to root infection involving the tooth affected greatly by carious decay. The resulting pulpal necrosis causes release of toxins at the apex of the tooth leading to periapical inflammation. This condition leads to the formation of reactive inflammatory (scar) tissue called granuloma further necrosis and damage stimulates the Malassez epithelial rests and resulting in the formation of a cyst that may be infected or sterile. These lesions can grow into large lesions because they apply pressure over the bone causing resorption¹. The toxin released by the breakdown of granulation tissue is one of the common causes of bone resorption.

Several treatment options exist for such cysts. Many small cysts resolve with endodontic therapy (‘root canal treatment’) of the involved tooth. Those lesions should be monitored to ensure such resolution. Cysts that fail to resolve with such therapy should be surgically removed. This is often accompanied by ‘apex resection’ of the tooth involved². This entails cutting off the end of the tooth and sealing, preventing the leakage of root canal filling.

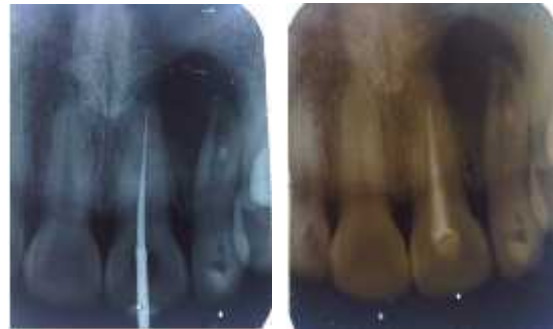
Case Report

Indonesian female, 24 years old was referred by her general practitioner dentist to Endodontic Division RSCM for intermittent pain, local swelling and suppuration in the region of the maxillary left second incisor (tooth 22). About four years earlier tooth 22 developed non-specific symptoms, which were managed by local periodontal treatment. Following that, the patient continued to experience intermittent mild discomfort during which the affected site would be treated with subgingival scaling and root planing. Then two years ago, the conditions deteriorated with pain, swelling and discharge of pus from the adjacent mucosa of tooth 22. However, apart from areas around tooth 22, the general periodontal status was normal. Tooth 21 and 22 did not respond to pulp vitality tests and was tender to percussion. The treatment plan was first to perform root canal treatment followed by periodontal treatment. Root canal treatment of tooth 21 and 22 was completed. However, the swelling from the area continued unabated. Then she referred to Department of

Oral and Maxillofacial Surgery RSCM General hospital.

On clinical examination Patient’s general condition was compos mentis and not on any medication. There was no history of systemic disease but patient had lung TBC and completely heal since January 2009. Extra oral condition within normal limit. Intra oral condition shows a swelling on tooth 22 vestibulum region. The swelling was cystic consistency, well defined border and 1 cm in diameter. Tooth number 21 and 22 was mobile 2 degrees.

The Endodontist who treat her, shows the serial photo of the tooth 21 and 22 treatment. On periapical radiography shows unilocular lesions in the periapical 21 and 22 region which 1 cm in diameter and are bordered by a thin rim of cortical bone. We diagnosed as radicular cyst caused by tooth 22.



June 10th 2011

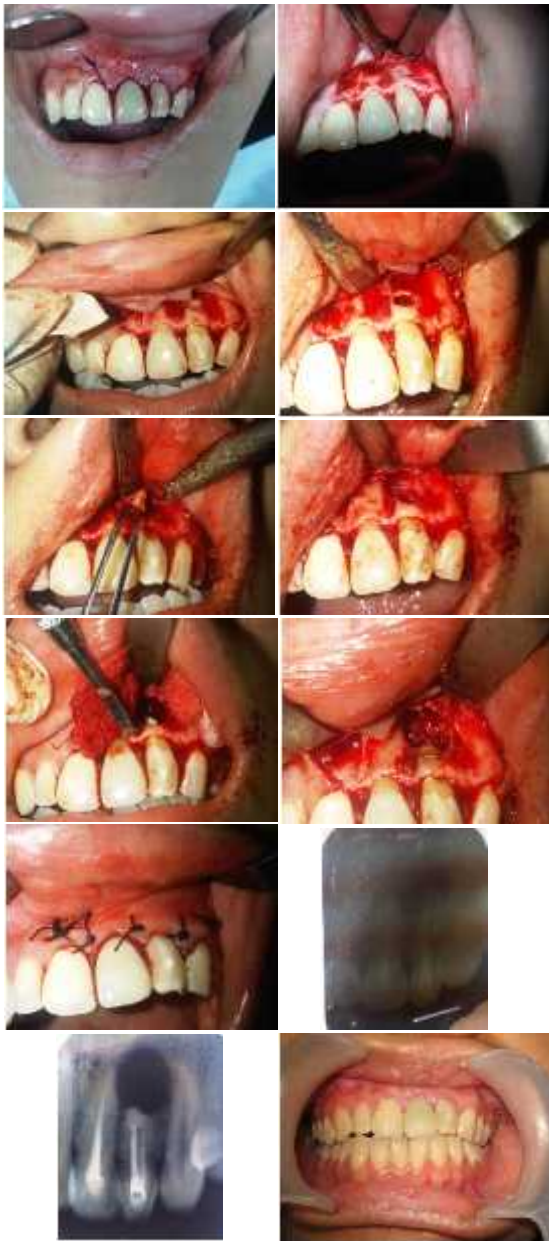June 17th 2011



June 30th 2011

Treatment plan

Two treatment options for tooth 22 were discussed with the patient. One was to perform apex resection and retrograde filling. The other was to extract it. In view of the previous less than optimal root canal treatment, it was proposed to the patient that an attempt to be made apex resection and retrograde filling tooth 22. The patient consented to the treatment plan after being comprehensively informed about the benefits and risks of the treatment.



DISCUSSION

An apex resection is the excision of the apical portion of a tooth root through an opening made in the overlying bone³. When conventional root canal treatment fails to keep a tooth healthy and symptom free, then surgical root canal treatment may be indicated to save the tooth. There are basically three reasons for failure of conventional root canal treatment. These include the following: 1. Accessory root canal system (miniature canals that contain necrotic (dead) material that cannot be reached with conventional root canal treatment. 2. A periapical lesion which not heal. 3. A vertical fracture in the root. The apex resection removes the accessory root canal systems that contain necrotic (dead)

material. If there is a periapical lesion after root canal treatment, this can be treated with apex resection and retrograde filling. If there is a vertical fracture in the root, then the tooth becomes non-restorable and must be extracted. In our patient, the periapical lesion (radicular cyst) is still persistent 3 months after root canal treatment and the tooth still mobile with dull pain on the region. This is the reason why apex resection with retrograde filling should be performed on our patient.

A triangular incision is made through the gum tissue close to the apical portion of the involved tooth. After the bone is exposed, a rotary drill instrument will be used to remove bone and expose the end of the root. The end of the root will be amputated and all adjacent infected tissue will be cleaned out. The root should be beveled from palatal to labial which makes the filling in the canal more visible. It is then possible to check the efficacy of the filling by visual inspection with sharp right angle explorer. The cut is made from mesial to distal and the bevel faces to the labial. The preparation is now ready for filling.

Different filler materials have been used, such as glass ionomers, IRM, amalgam or composite resins, with different results⁴. Torabinejad et al⁵ and Nakata et al⁶ suggested that MTA induces healthy apical tissue formation more often than other materials, as a result of the lesser inflammation produced. Zhu et al⁷ described increased human osteoblast adhesion to MTA and composite versus IRM and amalgam. Koh⁸ presented a clinical case in which MTA was used as retrograde filler material, with very good results. MTA has also been shown to adapt well to tissues in retrograde filling of an open-apex tooth. Regarding to this condition, we choose MTA as retrograde filling material to our patient.

Three weeks after the operation the patient had no complain and no sign of infection on the operation area. On periapical radiography shows that the apical tooth 22 was already filled in a proper way and the radicular cyst was completely enucleated. Radiographic evaluation will continue at three and six months prior to surgery.

CONCLUSIONS

Apex resection with retrograde filling has recently been used to treat periapical lesion such as radicular cyst. These are lesions

appearing in the apical zone of infected tooth, and which are cleaned and subjected to root canal treatment. Apex resection of the tooth may even be performed in order to avoid bacterial proliferation and relapse of the eliminated lesion with a good result. It needs to perform radiographic evaluation at least 3 months prior to the operation in order to evaluate the successful of the operation.

REFERENCES

1. Shear M. Cysts of the Oral Regions, 3 edition, Boston, Wright, 1992:136-70
2. Cohn SA. When all else fails. *Aust Endod J* 1998;**24**:128-9.
3. Stock C. "Textbook of endodontics 3rd ed Elsevier Mosby; 2004:225-47.
4. Duprez JP, Bouvier D, Bittar E. Infected immature teeth treated with surgical endodontic treatment and root reinforcing technique with glass ionomer cement. *Dental Traumatology* 2004; **20**: 233-40.
5. Torabinejad M, Ford TRP, Mc Kendry DJ, Abedi HR, Miller DA, Kariyawasam SP. Histologic assesment of MTA as root end filling in monkeys. *J Endodon* 1997;**23**:225-8.
6. Nakata TT, Bae KS, Baumgartner JC. Perforation repair comparing mineral trioxide aggregate and amalgama. *J Endodon* 1997;**23**:259-62
7. Zhu Q, Haglund R, Savafi K, Spangberg L. Adhesion of human osteoblasts on root-end filling materials. *J Endod* 2000;**26**:404-7.
8. Koh ET. Mineral trioxide aggregate (MTA) as a root end filling material in apical surgery—a case report. *Singapore Dent J* 2000;**23**:72-8.