Open Access

Int. J. Trop. Vet. Biomed. Res.
Vol. 5 (2): 7-12; November 2020

www.jurnal.unsyiah.ac.id/IJTVBR
E-ISSN : 2503-4715

The Effect of Ethanol Extract of Malacca Leaves *(Phyllanthus emblica)* on The Number of Fibroblast Cells in White Rats *(Rattus norvegicus)* Burns Wound

Ajirni[1], Nuzul Asmilia[2*], Nazaruddin[3], Amalia Sutriana[4], Dian Masyitha[5], Muhammad Isa[6]

[1]*Study Program of Veterinary Education, Faculty of Veterinary Medicine, Universitas Syiah Kuala*
[2]*Laboratory of Clinical, Faculty of Veterinary Medicine, Universitas Syiah Kuala*
[3]*Laboratory of Pathology, Faculty of Veterinary Medicine, Universitas Syiah Kuala,*
[4]*Laboratory of Farmacology, Faculty of Veterinary Medicine, Universitas Syiah Kuala,*
[5]*Laboratory of Histology, Faculty of Veterinary Medicine, Universitas Syiah Kuala,*
[6]*Laboratory of Chemistry, Faculty of Veterinary Medicine, Universitas Syiah Kuala,*
**Corresponding Author: nuzulasmilia@unsyiah.ac.id*

Abstract

Burns are caused by heat exposure, such as fire, radiation, electricity or chemicals that can damage the skin and affect the body's systems. The aim of this study was to find out the effect of the ethanol extract of Malacca leaves (*Phyllanthus emblica*) on the number of fibroblast cells in white rats (*Rattus norvegicus*) that have burned. This study used 24 white rats (*Rattus norvegicus*) were divided into 4 groups that smeared with aquadest as a negative control (P1), 5% ethanol extract gel of Malacca leaves (P2), 10% ethanol extract gel of Malacca leaves (P3), and positive control applied with bioplasenton® gel (P4). The IIA degree burn were created by placing a 2x2 cm hot iron plate on the back of the rat for 5 seconds. The euthanasia performed to all animal and the skin samples were collected after 15 days of treatment. Then histopathological preparations were made using HE staining. The number of fibroblast cells were analyzed by ANOVA test. The average number of white rats (*Rattus norvegicus*) fibroblast cells that suffered burns P1 (negative control) had a number of 7 ± 1.4 cells/visual. Whereas the P2 group had a number of 4.2 ± 1.58 cells/visual. This value has a significant difference with the negative control. But the P2 and P3 values (3 ± 1.51 cells/visual) there is no significant different with the P4 value (positive control) with an average number of P4 fibroblast cells were 2 ± 0.4 cells/visual. The results of this study concluded that the ethanol extract of malacca leaves 5% and 10% had an effect againts accelerating burns healing in white rats (*Rattus norvegicus*).

Keywords: burns, fibroblasts, malacca leaves (Phyllanthus emblica).

Background

Burns are tissues damaged caused by heat exposure, flame, steam, radiation, electricity, or chemicals (Jong, 2005). Extensive burns can affect the cellular function and metabolic processes. All systems will be disrupted, especially the cardiovascular system. The impact of cardiovascular disruption may reduce the burn recovery speed and survival of patient because every organ requires the constant blood supplies (Corwin, 2009).

Indonesia is a tropical country that has a high level of biodiversity. In Indonesia, the biodiversity of plants can be seen in various kinds. The utilization of tropical plants is one of the targets in the development of traditional medicine by using various kinds of plants that grow in tropical country (Thomas, 1989).

One of the plants that are often used as natural medicine is the malacca plant (*Phyllanthus emblica*). These plants have greenish stems, with the size variety is small to medium, and slightly yellowish-green flowers (Dhale, 2012). According to Fauzi *et al*. (2018), in the ethanol extract of the malacca leaves (*Phyllanthus emblica)* contains phytochemical compounds that are not much different from compounds in other plants. There are several compounds in malaca leaves extract (*Phyllanthus emblica*) that help the wound healing process, including flavonoids, tannins, and saponins.

Tannin is a potential compound that trigger the increasing number of fibroblast cells and developing capillary blood vessels when a new wound occurs (*Li et al.*, 2011). Saponin plays the formation of new epithelium which helps reduce the diameter

of the wound through the epithelialization process (Widyantoro and Sugihartini, 2015). Apart from being antioxidants, flavonoids act as anti-inflammatory that reduce inflammation and pain in the wound area (Iwan and Nur, 2010).

Fibroblasts are the main cells that appear in the first week that play a role in the wound healing process (Hidayat, 2013). The fibroblasts function is to produce collagen and improve in reducing the wound diameter (Darby *et al.*, 2014). Welding fibrils have a special phenotype under keratinocyte control called myofibroblasts (Werner *et al.*, 2007). Myofibroblasts are special fibroblasts that have similarities to smooth muscle cells that play a role in the extracellular junction of cells. This cell activity plays a role in the wound closure process due to tissue injury (Porter, 2007).

Based on the information above, the researchers are interested in conducting a study about ethanol extract of malacca leaves to determine the number of fibroblasts in white rats (*Rattus norvegicus*) that experienced burns after being given ethanol extract of the leaves of malacca (*Phyllanthus emblica*).

Materials and Methods

Ethical approval

This study has received ethical approval for the use of experimental animals from the Research Ethics Commission of the Faculty of Veterinary Medicine, Syiah Kuala University with Number 58 / KEPH / 2020.

Research procedure

Making Malacca Leaf Ethanol Extract Gel

In this study, gel preparation was carried out at concentration of 5% and 10%. According to Hamzah (2006), the standard gel formulation uses 5% Na-CMC, 10% glycerin, 5% Propylenglycol and the addition of distilled water to 100%.

The method of making gel works, the first step is to weigh all ingredients based on the formulation. Na-CMC is dissolved in a beaker filled with water that has been heated on a hot plate. Then the ethanol extract of the leaves of malacca was added according to each concentration and then stirred until the preparation became homogeneous. Furthermore, the addition of propylene glycol and distilled water slowly forming a consistent gel. The gel will be put in a gel pot and stored at room temperature.

Animal preparation

The use of 24 white rats in this study were placed in the cages of each treatment group for environmental adaptation process. Each cage contains 6 white rats for subsequent burns.

Creating burn wound in rats

Burns was made on the back of the rats. Before the burn was made, the hairs around the back were shaved with a diameter of 5 cm and then disinfected with 70% alcohol. Injectable general anesthetic ketamine-xylazine used to every rat, allow a few minutes until they loss of consciousness. Then, a 2x2 cm iron plate was attached which was connected with electric solder for 5 seconds to the back of the rats until it formed IIA degree burns. This burn is characterized by the occurrence of blisters and peeling skin on the part where the iron plate is attached (Laila *et al.*, 2011).

Burn treatment on rats

Burn treatment is carried out according to each treatment. There were 4 treatment groups, the negative control group (P1) was given distilled water, the treatment group (P2) was rubbed with 5% malacca leaf ethanol extract gel, the treatment group (P3) was applied 10% malacca leaf ethanol extract gel, and the positive control group (P4) was applied bioplacenton ® gel. Apply twice a day every morning and evening for 15 days.

The histopathological preparations

The preparation of histological specimens refers to the Kiernan method (1990). Skin samples were fixed in a 10% Neutral Buffer Formalin (NBF) solution, then cut to a size of 1x1x1 cm3. Perform the tissue dehydration process using a stratified concentration of alcohol solution (80%, 90%, 96%, and absolute), purify the

preparations using a xylene for 2 repetitions for 2 hours, infiltration is carried out in liquid paraffin which is carried out 3 times for 1 hour, and continued with planting (embedding) until it becomes a paraffin block (blocking). This block then sliced (sectioning) using rotary microtome with a thickness of 5 μm and then placed in a tissue bath with a temperature of 50°C. The sliced samples were taken using the object-glass and then dried on hot plate until the samples ready to stain.

Hematoxylin-Eosin (HE) Staining

The staining procedure require all the tissue slides proceed in deparaffinization step by immersing them into xylene for 2 minutes. Then the dehydration process was carried out with absolute alcohol, 96% alcohol, and 90% alcohol for 2 minutes for each concentration. The tissue slides were washed with distilled water for 2 minutes. The next step is to immerse the slides in hematoxylin solution for 5 minutes, then wash the slides with distilled water for 2 minutes. Next, put the slides into the acid alcohol by dipping them 3 times, then washed in distilled water 4 dips. Then the slides were put into the eosin solution for 5 minutes. After eosin solution step, all slides put into dehydration solution using 96% alcohol and absolute alcohol for 2 dips. Then do the clearing process using a xylene for 2 minutes. The final step is mounting with Entellan®.

Histopathological observations

Histopathological observations using an Olympus CX31 light microscope connected to computer. The application Top View 3.7 was used to calculate the number of fibroblasts with 400x magnification and 30 μm scale bar.

Data analysis

The number of fibroblasts were analyzed with analysis of variance (ANOVA) statistical test and continued with the Duncan test.

Results and Discussion

The results of fibroblast cells number after being treated with ethanol extract of malacca leaves (*Phyllanthus emblica*) can be seen in Figure 1.

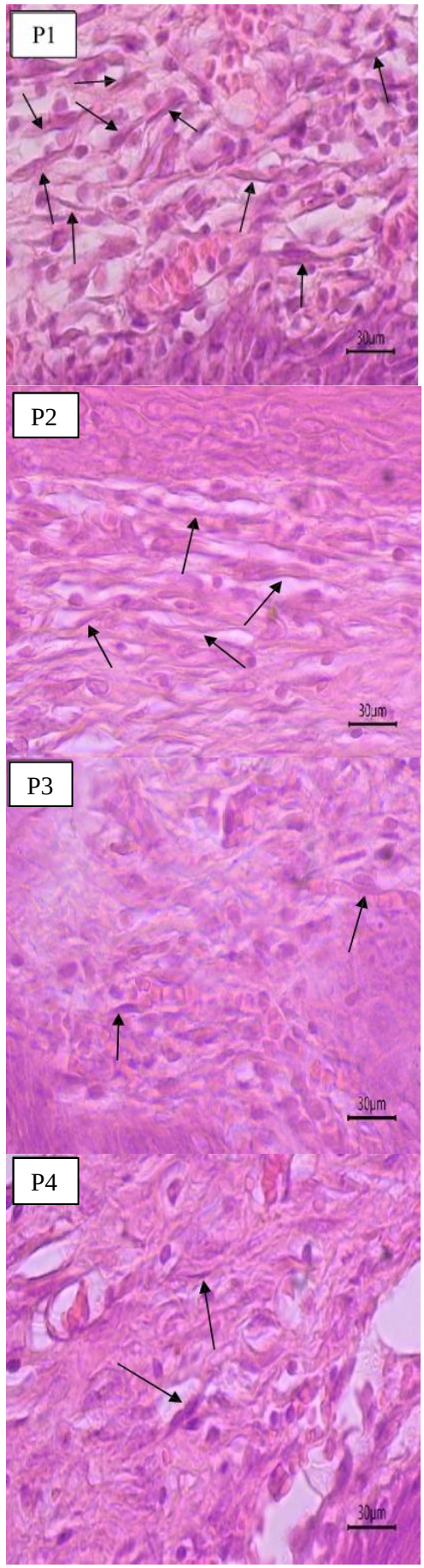

Figure 1. Comparison of the number of fibroblasts.

Note: negative control (P1) = aquades treatment group, P2 = ethanol extract gel treatment group 5% concentration of malacca leaves, P3 = group of concentrated ethanol extract gel of malacca leaves 10%, and P4 = the bioplasenton® gel treatment group.

The wound healing is a biological process that occurs in the body which includes 3 main phases, there are the inflammatory phase, the proliferation phase, and the remodeling phase. Fibroblasts appeared in the proliferation phase on the 4th day and the most fibroblasts recorded on the 7th day. Fibroblasts are very important in this phase; therefore, this phase also called the fibroplasia phase. Fibroblasts will move actively to wound area and suopport the proliferating tissue, then they will synthesize collagen to produce granulation tissue that will cover the wound (Hidayat, 2013). The histopathological picture of fibroblast cells can be seen in Figure 1. In this picture, fibroblasts appear in a fusiform that extends like smooth muscle between the tissue fibers and has a round nucleus like an egg.

The results of the mean number of fibroblast cells in each treatment group in rat (*Rattus norvegicus*) ± SD can be seen in Table 1. Based on Table 1. there was a decrease in the number of fibroblast cells of white rats (Rattus norvegicus) that experienced burns in the P2 and P3 treatment groups that were given malacca leaves ethanol extract gel treatment (*Phyllanthus emblica*). Then, a very rapid increase in the number of fibroblasts occurred in the P1 treatment group which was given aquades as a negative control. The Duncan test results showed a significant difference between the negative control group, the group giving malacca leaves ethanol extract gel (*Phyllanthus emblica*), and the positive control.

The mean number of fibroblasts in P1 groups (negative control) had a total of 7 ± 1.4a cells/field of view. Meanwhile, group P2 has a total of 4.2 ± 1.58b cells/field of view. This value has a significant difference between the P1 and P2 groups. But the values of P2 (4.2 ± 1.58b cells/field of view) and P3 (3 ± 1.51b cells/field of view) were not significantly different from the value of P4 as a positive control with an average number of P4 fibroblast cells of 2 ± 0.4b cells/field of view. This means there is an effect of malacca leaves ethanol extract gel (*Phyllanthus emblica*) on reducing the number of fibroblast cells of white rats (*Rattus norvegicus*) having burn wound. In line with the statement of Ambiyani (2013), the decrease of fibroblasts number indicates that the wound healing process is progressing rapidly and running normally.

Table 1. The number of fibroblast cells in *Rattus norvegicus*

Treatment Group	Number of Fibroblast Cells ± SD
P1	7 ± 1.4^{a}
P2	4.2 ± 1.58^{b}
P3	3 ± 1.51^{b}
P4	2 ± 0.4^{b}

Note: $^{a, b}$ Different superscripts show significant differences ($p<0.05$)

P1 = Treatment with distilled water, P2 = Treatment with 5% concentration of malacca leaf ethanol extract gel, P3 = Treatment with 10% concentration of malacca leaf ethanol extract gel, P4 = Treatment with bioplacenton® gel.

The presence of fibroblasts greatly affects the speed of the burn healing process, because fibroblasts function as producers of collagen fibers. Collagen fibers will uniting between each other and make wound tightly closed to generate the healing run optimally (Barbul, 2005). Moreover, there are some compounds in malacca leaf extract (*Phyllanthus emblica*) can accelerate the burn wound healing process such as tannins, saponins, and flavonoids (Fauzi *et al.*, 2018).

Tannin compounds help in the process of forming new capillaries and increasing the number of fibroblasts (Li *et al.*, 2011). In addition to helping the epithelialization process, the saponin compounds in malacca leaves can induce the formation of collagen, thereby accelerating the healing process of burns (Rismana *et al.*, 2013). While flavonoid compounds in

addition to acting as antioxidants and antibacterials are also able to increase the activation and proliferation of fibroblasts, which trigger collagen formation and accelerate the wound healing process (Barbul, 2005).

From the analysis of the ANOVA test (Table 1), the 5% and 10% concentrations of the ethanol extract gel of the malacca leaves (*Phyllanthus emblica*) can affect the burn wound healing process in white rats (*Rattus norvegicus).* Then, the results of the analysis showed that the bioplasenton® gel treatment had no significant difference with the ethanol extract gel treatment group of Malacca leaves (*Phyllanthus emblica*). It can be concluded that the ethanol extract of the malacca leaves (*Phyllanthus emblica*) gel and the bioplasenton® gel has almost the same effect.

Conclusion

From the results of the study, it can be concluded that the ethanol extract gel of the malacca leaves (*Phyllanthus emblica*) with a concentration of 5% and 10% affects the healing of burns in white rats (*Rattus norvegicus*) as evidenced by the decrease in the number of fibroblast cells, namely 4.2 ± 1.58 b cells/field.

References

Ambiyani, W. 2013. Pemberian salep ekstrak daun mengkudu (*Morinda citrifolia* L.) meningkatkan proses regenerasi jaringan luka pada tikus putih galur wistar (*Rattus norvegicus*) jantan. *Tesis*. Program Magister Program Studi Ilmu Biomedik Program Pascasarjana Universitas Udayana, Denpasar.

Barbul, A. 2005. *Wound Healing*. In: F. Charles Brunicardi, Dana K., Andersen, Timothy R., Billiar, David L., *et al.*, eds. Schwartsz's principles of surgery. 8th ed. New York: McGraw-Hill Companies.

Corwin, E. J. 2009. *Buku Saku Patofisiologi*. EGC, Jakarta.

Darby, I.A. and Hewitson, T.D. 2007. Fibroblast differentiation in wound healing and fibrosis. *International Review of Cytology*, 257: 143-79.

Dhale, D.A. 2012. Pharmacognostic evaluation of Phyllanthus *emblica* Linn (Euphorbiaceae). *Int. J. Pharm. Bio. Sci*, 3(3): 210-217.

Fauzi, N.I., S.A. Ardiansyah, and Hidayat. 2018. Screening of mechanism of action of malaka leaves (*Phyllanthus emblica L.*) as anti-diabetic. *Jurnal Tm Conference Series*. 1(3): 107-111.

Hidayat, T.S.N. 2013. Role of topical extract aloe vera gel in deep burn wound healing in rat. *Thesis*. Airlangga University School of Medicine.

Iwan, J. and Nur, A. 2010. The comparation between topical Aplication Of the Aqueous Leaf Extract of *Carica Papaya* (ALEC) & khaula honey in accelerating skin wound healing in mice (*Mus musculus*). *Majalah Kedokteran Bandung*, 42(2): 76-81.

Jong, W. 2005. *Buku Ajar Bedah*. EGC, Jakarta.

Kiernan, J. A. 1990. *Histological & Histochemical Methods: Theory and Practice*. 2nded. Pergamon Press, Oxford.

Laila, L., F. Febriyenti, F.M. Salhimi, and S. Baie. 2011. Wound healing effect of haruan (*Channa striatus*) spray. *International Wound Journal*, 8(5): 484-491.

Li, K., Y. Diao, H. Zhang, S. Wang, Z. Zhang, B. Yu, S. Huang, H. Yang. 2011. Tannin extracts from Immature fruits of *terminalia chebula fructus* Retz. promote cutaneous wound healing in rats. *BMC Complementary and Alternative Medicine*, 11(86): 1-9.

Porter, S. 2007. The role of the fibroblast in wound contraction and healing. *Wounds UK*, 3(1): 33-40.

Rismana, E., R. Idah, Y. Prasetyawan, B. Olivia, dan Y. Erna. 2013. Efektivitas Khasiat Pengobatan Luka Bakar Sediaan Gel Mengandung Fraksi Ekstrak Pegagan Berdasarkan Analisis Hidroksiorolin dan Histopatologi pada Kulit Kelinci. *Penelitian Kesehatan*. 41: 45-60.

Thomas. 1989. *Traditional Medicinal Plants.* Kanisius, Yogyakarta.

Werner, S., T. Krieg, and H. Smola. 2007. Keratinocyte-fibroblast interaction in wound healing. *Journal of Investigative Dermatology*, 127: 998-1008.

Widyantoro, O.B. and Sugihartini, N. 2015. Evaluation of physical properties and activity test of extract of (*Leucaena glauca*), benth leaves in variation type of base ointment as wound. *Media Farmasi*, 12(2): 186-198