

Management of Post-traumatic Dental Immature Teeth at the Growing Phase

Yufita Fitriani, Eriza Juniar

Pediatric Dentistry Department, Faculty of Dentistry, Universitas Hang Tuah, Surabaya, Indonesia

*Corresponding Author: email: yufita.fitriani@hangtuah.ac.id

ARTICLE INFO : Received, July 23., 2023; Revised, August 10, 2023; Accepted, October 10, 2023; Published; December 20, 2023
ORCID : Fitriani Y ([0000-0002-9633-4843](https://orcid.org/0000-0002-9633-4843)); Juniar E ([0009-0005-3267-0441](https://orcid.org/0009-0005-3267-0441))
DOI : [10.24815/jds.v8i2.34652](https://doi.org/10.24815/jds.v8i2.34652)

ABSTRACT

Background: Anterior dental trauma is common in children. Traumatic dental injury in children's teeth can interfere with the function of speech, mastication, aesthetics, eruption of permanent teeth, and the growth and development of teeth and jaws. An unclosed and wide-open apex (immature tooth) is a complex case for a pediatric dentist due to multiple stages of treatment and different options compared to adults. **Objective:** To explain the management of post-traumatic dental immature teeth. **Case:** An eight-year-old male child came to the clinic one month after getting a dental injury. This case is classified into Class IV Ellis and Davey's traumatic dental injury classification with immature teeth. **Case Management** Apexification uses Ca(OH)₂ paste followed by an acrylic provisoris restoration while the jaw grows. **Conclusion:** Apexification using Ca(OH)₂ paste followed by acrylic provisions crown restoration is a proper treatment in this case.

Keywords: dental injury; apexification; Immature teeth; growing child

ABSTRAK

Latar Belakang : Trauma gigi anterior pada anak seringkali kita temui pada anak-anak. Trauma yang terjadi pada gigi anak-anak dapat menyebabkan gangguan pada fungsi bicara, mengunyah, estetika, pertumbuhan dari gigi permanen pengganti serta pertumbuhan geligi dan rahang pasien. Ujung apikal gigi yang masih terbuka (gigi *immature*) adalah sebuah kasus yang kompleks untuk seorang dokter gigi anak. Kasus ini membutuhkan perawatan *multiple* dan bertahap serta pilihan perawatan yang berbeda dibandingkan pada kasus serupa yang terjadi pada orang dewasa. **Tujuan :** Untuk menjelaskan tata cara perawatan post trauma gigi *immature* pada anak. **Kasus :** Seorang anak laki-laki berusia 8 tahun datang ke klinik dengan keluhan 1 bulan pasca trauma gigi anterior. Kasus ini digolongkan menjadi Klasifikasi Ellis and Davey Klas IV disertai ujung apikal yang terbuka. **Perawatan kasus :** Apeksifikasi menggunakan pasta kalsium hidroksida (Ca(OH)₂) diikuti dengan perawatan restorasi provisoris akrilik ketika rahang masih dalam tahap pertumbuhan rahang. **Kesimpulan :** Apeksifikasi menggunakan pasta kalsium hidroksida (Ca(OH)₂) dan diikuti dengan perawatan restorasi provisoris akrilik adalah perawatan yang sesuai pada kasus tersebut
Kata Kunci : cedera gigi, apeksifikasi, Immature teeth, anak pada masa tumbuh kembang

1. Introduction

Anterior dental trauma is common among children because their coordination and judgment of their surroundings have not fully developed, causing them to fall when walking, running, playing, and exercising frequently. Damages to children's teeth can impair their speech, chewing, aesthetic functions, and permanent teeth eruption, which impede their teeth and jaw development and growth¹.

Root growth and apical root closure will occur until three years after teeth eruption. Caries, trauma, and other pulp disorders during root formation can cause dentin formation and root growth to stop. This causes the periapical of the teeth to open.² The most recent guideline in 2021 from the International Association of Dental Traumatology (IADT), validated together with the American Academy of Pediatric Dentistry (AAPD), stated that treatment for younger age groups is different from that for adults, mainly due to immature teeth and potential growth during puberty.³ Teeth with open apex and pulp or periapical disorder may have problems. Teeth with open apices often tend to have thin dentinal walls susceptible to fracture before, during, or after endodontic treatment. Frequently, they present with periapical lesions, which may or may not be associated with apical resorption. Short roots compromise the crown-root ratio, often affecting long-term prognosis. Large

open apices pose a challenge in determining the working length, the necessity of root canal preparation, and achieving control during obturation.

Teeth with open apices are not indicated in the conventional root canal treatment. The treatment success rate is also challenging to predict. This is a considerable endodontic problem.^{2,4} Apexification is one of the alternative treatments for immature teeth with open apex for nonvital teeth. This treatment can induce an apical barrier, allowing further endodontic treatments.² Apexification is followed by adequate root canal treatment and tooth restoration to achieve tridimensional sealing to prevent reinfection. Ca(OH)₂ is a common apexification material because it does not contain harmful periapical reactions, in addition to its predictable result and ability to mix with several different substances (mono-chlorophenol, saline, anesthetic fluid, chlorhexidine, and creating) to induce apical closure.⁵ The management of nonvital apexification treatment and restoration after post-traumatic dental immature teeth are essential to maintain the vital function of the teeth.

2. Case Report and Case Management

2.1. Case Report

An eight-year-old male patient and his parent visited the clinic and asked for treatment for his broken upper left front teeth due to an accident while cycling one month ago. When falling one month ago, he felt pain in his teeth and bled, and the pain was gone after taking paracetamol for three days. The patient visited the clinic to have a dental treatment. The objective extra- and intraoral examinations were performed, and the extraoral clinical examination found no abnormality. Intraoral clinical examination showed a fracture expand from the enamel to the pulp space on the upper left central incisor (21- WHO classification).

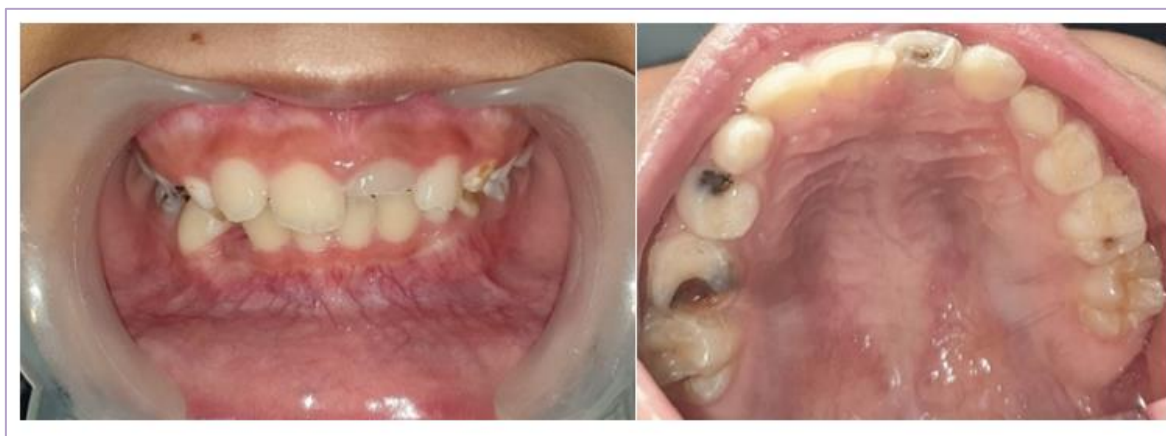

Figure 1. Preoperative of Intra-Oral

The dental traumatic classification in this case is Class IV Ellis and Davey's fracture classification. The clinical examination showed sensitivity on percussion and palpation tests, nonvital pulp, and internal discoloration on 21. Thus, 21 was diagnosed as pulp necrosis. Teeth 21 showed a fracture on the crown until the pulp space was exposed, followed by the immature apical apices and periapical lesion area diagnosed as a periapical abscess (Fig 1). The periapical image strengthened the diagnosis of pulp necrosis and immature apices. The patient was treated after the parents delivered the informed consent (Fig 2).

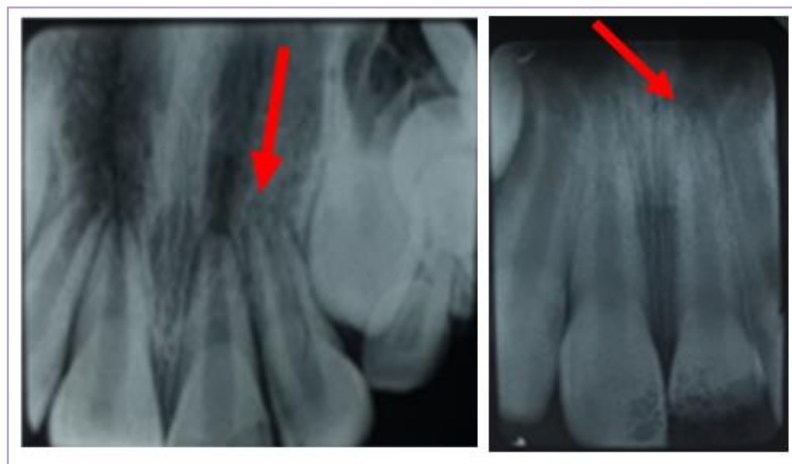


Figure 2. Preoperative of periapical

2.2 Case Management

During the first visit, the access opening was done to get drainage of the periapical lesion, and then the remaining necrotic pulp tissue was removed by inserting, rotating, and withdrawing a small size Niti KFile, and root canal irrigation was performed using 1,25% sodium hypochlorite and saline to eliminate irritant and necrotic tissue leftovers in the root canal. Then, a diagnostic wire photo was taken to obtain the working length (Fig 3).

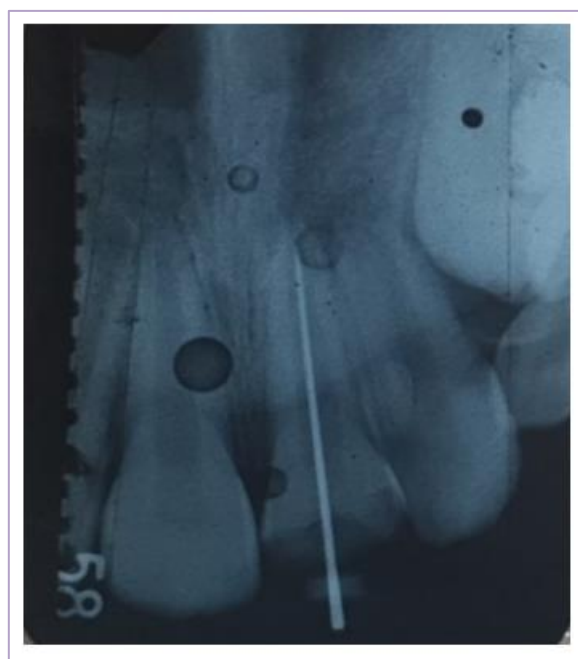


Figure 3. 21 Diagnostic Wire Photo (DWP)

After performing Diagnostic Wire Photo, Instrumentation was served with a gentle circumferential filing motion, beginning with a relatively small file and progressing through the file sizes. Begin with the 10-sized Nickel Titanium File, followed by 15, 20, 25, 30, 35, and 40 files. The aim was to maximize cleansing, aided by copious irrigation with 1,25 % sodium hypochlorite and saline. Paper points were used to dry the canal. Instrumentation beyond the apical was avoided. Then, **Ca(OH)₂ paste (metapaste®)** was applied according to the working length with mild pressure. The evaluation was made after 1 and 3 months after (Fig 4).

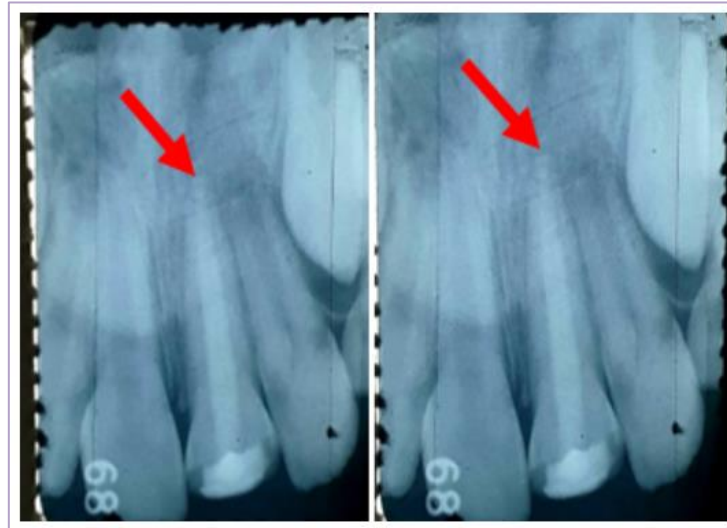

Figure 4. Ca(OH)_2 Application

Barrier calcification closure evaluation was formed one month after Ca(OH)_2 application through periapical x-ray and clinical assessment. However, the root canal dressing was continued to complete the barrier calcification formation. Hence, Ca(OH)_2 paste was removed from the root canal by irrigating the root canal with 1,25 % sodium hypochlorite and saline. Then, Ca(OH)_2 paste was reinserted according to the working length. The evaluation was made three months later (Fig 5A). After three months, the assessment was performed by taking a periapical x-ray and using a small Niti Kfile #8 to sense the apical stop of the previously immature tooth. The presence of an apical stop indicates a complete barrier calcification. The periapical image also clearly showed that the apical edge of the tooth has been closed and looks rounder compared to the pre-treatment condition (Fig 5B). After barrier calcification was formed, the treatment was continued by gutta-percha radiograph trial according to the working length. Then, the root canal is filled by gutta-percha and the resin-based sealer permanently by lateral condensing method due to a wide root canal and filled by glass ionomer cement restoration (Fig 5C).

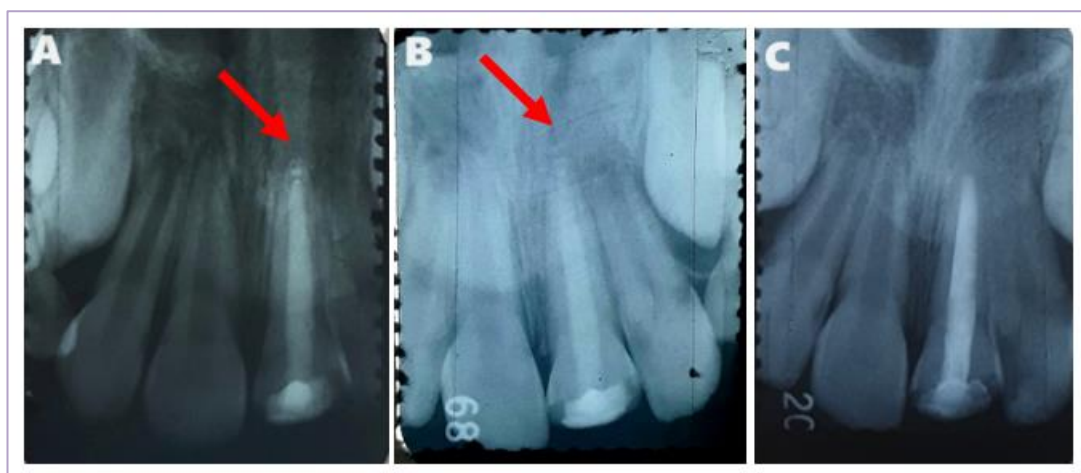

Figure 5. (A) 1-month after Ca(OH)_2 Application, (B) 3 months after Ca(OH)_2 Application, (C) Root canal filling with resin-based sealer and gutta-percha

The provisional acrylic crown was selected for restoration one week after the clinical evaluation of root canal filling. In this case, the patient is determined without post-placement because the patient is still in the dentoalveolar developmental phase (growing phase) to avoid recurrent adjustment. The crown material was lightweight to avoid excessive weight for the rest of the tissue, preventing the rest of the tissue from being fractured until the patient reached an optimal age for further complex restoration. **An acrylic crown is also chosen for its low-cost treatment.**

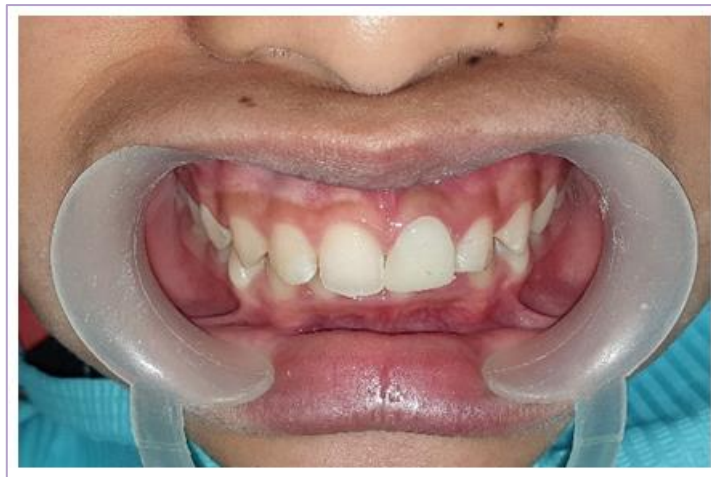

Figure 6. Acrylic crown

3. Discussion

Immature teeth with open apices and periapical disorders commonly cause problems in endodontic treatments. Open apical is not indicated in the conventional root canal treatment. The treatment success rate is difficult to predict.²⁴ Endodontic management of children's immature, nonvital teeth is a huge challenge for pediatric dentists. Apical closure is pivotal to obtaining a complete tridimensional sealing. A perfectly closed root canal system can prevent microorganisms and microorganism products and increase the success rate of endodontic treatment⁶.

In this case, the patient was an 8-year-old child between 2 years after a 21-year tooth eruption. Thus, the apical edge of the tooth has not entirely closed. The preoperative periapical image showed that the apical edge of all maxillary incisors has not been completely closed yet. The definitive treatment for this case is apexification. This apexification treatment stimulates apical barrier formation to allow further endodontic treatment. Apexification was performed on nonvital left maxillary central incisor necrosis immediately and was evaluated 1 and 3 months after the procedure until the apical barrier was performed. The treatment is followed by adequate root canal treatment and restoration to achieve tridimensional sealing to prevent reinfection.

The dressing material chosen in this case was the non-setting $\text{Ca}(\text{OH})_2$ to allow a more straightforward cleaning process once the apical has perfectly closed. It mainly contains $\text{Ca}(\text{OH})_2$ and barium sulfate as an opacifier agent. An opacifier agent was added to make evaluating apical barrier formation easier through a radiograph. $\text{Ca}(\text{OH})_2$ was the primary material stimulating the apical barrier or calcified bridge at the apical edge. The $\text{Ca}(\text{OH})_2$ action mechanism is achieved by dissolving Ca^{2+} and ion OH^- from $\text{Ca}(\text{OH})_2$. The effect of these materials on vital tissues is that they induce the formation of hard tissue in the apical edge in the form of a calcified bridge and provide antimicrobial benefits⁷. Another case was done by Niussha Abazarian *et al.* using $\text{Ca}(\text{OH})_2$ as the root canal medication to stop the external resorption process. The external resorption occurred after a failure of cervical pulpotomy treatment from a traumatic dental injury case, and by the 9-month follow-up, the process of resorption had been stopped.

The $\text{Ca}(\text{OH})_2$ prevents inflammatory resorption with a high degree of success.⁸ A meta-analysis study by Fabrizio Gerrero *et al.* concluded that apexification by calcium hydroxide has been applied for many years as a valid therapy to treat apexification.⁹ $\text{Ca}(\text{OH})_2$ is a common apexification material because it does not contain harmful periapical reactions, has predictable results, and has several different substances⁵. The deposition process of Ca^{2+} from $\text{Ca}(\text{OH})_2$ is reported to stimulate the regeneration of bone tissue around the lesion.¹⁰ $\text{Ca}(\text{OH})_2$ induces the formation of calcified

barrier and apical healing by stimulating cellular activity of Hertwig's epithelial root sheath and its branches, epithelial rest of Malassez, and potential osteogenic of Ca(OH)₂. Hertwig's epithelial root sheath plays a significant role in apical barrier formation. Epithelial cells resist periapical inflammation and induce root closure during the inflammation elimination process¹¹.

Provisional restoration is chosen using an acrylic crown without a post placement. This treatment is preferred because the patient is still developing dentoalveolar. Vertical and horizontal growth of the maxilla will cause the post to be unfit and require more adjustments. Other crown materials are not considered in this case due to the more significant removal of the original crown tissue required.¹² The material selection should be based on several criteria, including the length of time the provisional crown will be used, strengths and weaknesses of the particular material relative to the clinical situation, and personal preference and experience of the operator in using a material. The literature tends to favor using acrylic resin as the material of choice when making provisional restoration.¹³

Using acrylic crowns as a provisional restoration is well-accepted and common in permanent teeth. The mechanical and aesthetic features of polymethyl methacrylate provisional restoration on permanent teeth have been extensively studied.¹⁴ In addition, an acrylic crown as a provisional crown offers a better economic advantage than a crown made of other materials like porcelain fused to metal (PFM) or zirconia crown, particularly when associated with facial and jaw growth of patients that likely require frequent crown adjustment, acrylic crown provide a better low-cost treatment.¹³ provisional restoration is the key to success in a complex and comprehensive case. A provisional crown offers the stability the operator needs to have adequate time. A temporary crown gives time for each stage of treatment, which should be finished before starting the next stage¹⁵.

In this case, the post and permanent crown treatment will be performed after the growth spurt phase ends to minimize recurrent adjustment. It should be noted that treatments for immature teeth in children differ from those in adults, as it is associated with children's potential facial and jaw growth. Thus, it is essential for a pediatric dentist to properly understand the management of post-traumatic treatment for immature teeth in children, from apexification to induce apical closure to post-root canal treatment restoration choices, by considering the child's ongoing facial and jaw growth. Apexification using Ca(OH)₂ paste (metapaste®) followed by a acrylic provisoris crown restoration is a proper treatment in this case due to the child's ongoing facial and jaw growth.

4. Conclusion

Apexification using Ca(OH)₂ paste (metapaste®) followed by a acrylic provisions crown restoration is proper treatment in this case due to the child's ongoing facial and jaw growth.

5. References

1. Jeffrey A. Dean and Kevin J. Donly. CHAPTER-11 Restorative Dentistry. McDonald and Averys Dentistry for the Child and Adolescent. 2016. 185-205 p.
2. Jaikaria A, Negi P, Kukreja S. Apexification: Use of MTA and Biodentin to form apical barrier in immature permanent teeth. ~ 156 ~ International Journal of Applied Dental Sciences. 2019;5(4):156-8.
3. Bourguignon C, Cohenca N, Lauridsen E, Flores MT, O'Connell AC, Day PF, et al. International Association of Dental Traumatology guidelines for the management of traumatic dental injuries: 1. Fractures and luxations. Dental Traumatology. 2020;36(4):314-30.
4. Forghani M, Parisay I, Maghsoudlou A. Apexogenesis and revascularization treatment procedures for two traumatized immature permanent maxillary incisors: a case report. Restor Dent Endod. 2013;38(3):178.
5. Lin JC, Lu JX, Zeng Q, Zhao W, Li WQ, Ling JQ. Comparison of mineral trioxide aggregate and calcium hydroxide for apexification of immature permanent teeth: A systematic review and meta-analysis. Journal of the Formosan Medical Association. 2016;115(7):523-30.
6. Mounir MMF, Farsi JMA, Alhazzazi TY, Matar MA, El-Housseiny AA. Characterization of the apical bridge barrier formed following amelogenin apexification. BMC Oral Health. 2018;18(1):1-8.
7. Baranwal R, Singh B, Dubey A, Avinash A. Review article Calcium Hydroxide in Dentistry. Journal of App. 2016;2(3):3-7.
8. Abazarian N, Milani S, Hamrah MH, Shahrabi MS. Management and Follow-Up of Complicated Crown Fractures with Intrusive Luxation of Maxillary Incisors in an 8-Year-Old Boy. Case Rep Dent. 2021;2021:5-10.

9. Guerrero F, Mendoza A, Ribas D, Aspiazu K. Apexification: A systematic review. *Journal of Conservative Dentistry*. 2018;21(5).
10. Orucoglu H, Cobankara FK. Effect of Unintentionally Extruded Calcium Hydroxide Paste Including Barium Sulfate as a Radiopaquing Agent in Treatment of Teeth with Periapical Lesions: Report of a Case. *J Endod*. 2008;34(7):888-91.
11. Chowdhury A, Alam A, Sarkar U, Mahmud A, Habiba U, Rabby M. Apexification with Calcium Hydroxide: 27 Months Follow Up of a Case. *Med Today*. 2013;25(1):42-5.
12. Thilander B. Dentoalveolar development in subjects with normal occlusion. A longitudinal study between the ages of 5 and 31 years. *Eur J Orthod*. 2009;31(2):109-20.
13. Siobhain Davis. The provisional crown. *Journal of the Irish Dental Association* [Internet]. 2004 Feb;50(4):167-72. Available from: <https://www.researchgate.net/publication/8113969>
14. Jathar P, Panse A, Desai A. Acrylic crowns for esthetic rehabilitation of primary teeth. *International Journal of Pedodontic Rehabilitation*. 2018;3(1):42.
15. Mizrahi B. Temporary restorations: the key to success. *Br Dent J*. 2019;226(10):761-8.

Authors Contribution

Contribution	Fitriani Y	Juniar E
Concepts or ideas	√	√
Design	√	√
Definition of intellectual content	√	
Literature search	√	√
Experimental studies	√	
Data acquisition	√	√
Data analysis	√	√
Statistical analysis	√	
Manuscript preparation	√	
Manuscript editing	√	√
Manuscript review	√	√



JDS (Journal of Syiah Kuala Dentistry Society) is an Open Access Journal licensed under a Creative Commons Attribution-ShareAlike 4.0 International License. This license authorizes the utilization, replication, modification, distribution, and reproduction of the article in any medium or format, provided that due credit is given to the original Author (s) and the source, a link to the Creative Commons license is provided, and any alterations made to the article are duly indicated.

Citation Format: Fitriani Y, Juniar E: Management of post-traumatic dental immature teeth at the growing phase. *J Syiah Kuala Dent Soc*. 2023; 8(2): 124-130.

Publisher's Note: The authors of this article assert that all claims made herein are exclusively their own and may not necessarily reflect the views of their respective affiliated institutions or those of the publisher, editors, and reviewers. The publisher does not provide any guarantee or endorsement for any product subject to evaluation in this article or any claim made by its manufacturer.