

THE EFFECT OF *Moringa oleifera* LEAF EXTRACT ON THECA CELL IN POLYCYSTIC OVARY SYNDROME MODEL WITH INSULIN RESISTANCE

Lisa Purbawaning Wulandari^{1*} and Anindya Hapsari²

¹Midwifery Department, Politeknik Kesehatan Kemenkes Malang, Malang, Indonesia

²Public Health Department, Faculty of Sport Science, Universitas Negeri Malang, Malang, Indonesia

*Corresponding author: lisa_purbawaning@poltekkes-malang.ac.id

ABSTRACT

The use of *Moringa oleifera* as an anti-oxidant should be investigated as an alternative treatment of follicular refinement in Polycystic ovary syndrome (PCOS) with insulin resistance. We aimed to prove the effect of *Moringa oleifera* leaf extract in various dosages to decrease the theca cell thickness of PCOS female rat with insulin resistance. This study was a laboratory experimental research. Three month old *Rattus norvegicus* strain Wistar rat weighing 100-130 g were divided into 5 groups (n= 8). PCOS model obtained by giving injection of testosterone propionate for 28 days, followed by metformin therapy and *Moringa oleifera* leaf extract at 250 and 500 mg/kg BW for 14 days. The examination of ovarium histology showed that leaf extract *Moringa oleifera* 500 mg/kg BW (0.931±0.457) significantly decreased the thickness of theca cells (P<0.05) compared to the PCOS control group. The conclusion was *Moringa oleifera* leaf extract as an anti-oxidant proven to decrease the thickness of theca cell of the female rat model of PCOS.

Key words: *Moringa oleifera*, polycystic ovary syndrome, theca cell thickness

ABSTRAK

Penggunaan *Moringa oleifera* sebagai antioksidan diteliti sebagai salah satu terapi alternatif untuk memperbaiki folikel pada Sindroma ovarium polikistik (SOPK) dengan resistensi insulin. Penelitian ini bertujuan membuktikan pengaruh ekstrak daun *Moringa oleifera* berbagai dosis untuk menurunkan ketebalan sel teka pada tikus model SOPK dengan resistensi insulin. Penelitian ini merupakan penelitian eksperimental dengan menggunakan tikus *Rattus norvegicus* strain Wistar berumur 3 bulan, bobot badan 100-130 g, yang kemudian dibagi menjadi 5 kelompok (n= 8). Model SOPK dilakukan dengan memberikan injeksi testosteron propionat selama 28 hari, dilanjutkan dengan terapi metformin dan ekstrak daun *Moringa oleifera* dosis 250 dan 500 mg/kg bobot badan selama 14 hari. Pemeriksaan histologi ovarium menunjukkan bahwa ekstrak daun *Moringa oleifera* dosis 500 mg/kg bobot badan (0,931±0,457) dapat menurunkan ketebalan sel teka secara signifikan dibandingkan dengan kelompok kontrol SOPK (P<0.05). Disimpulkan bahwa ekstrak daun *Moringa oleifera* sebagai antioksidan mampu menurunkan ketebalan sel teka pada tikus model SOPK.

Kata kunci: *Moringa oleifera*, sindroma ovarium polikistik, ketebalan sel teka

INTRODUCTION

Polycystic ovary syndrome (PCOS) is known as the commonest endocrine disorder in women of reproductive age (Umayal *et al.*, 2019). It affects about 5 to 10% of women of reproductive age (Homburg, 2008). The definition of PCOS includes both clinical and biochemical criteria as well as ovarium morphology. Women with regular cycles and recognized hyperandrogenism could be part of this syndrome. Polycystic ovary syndrome during adolescence can be diagnosed when there were 2 of the following 3 classic features are confirmed (Fauser *et al.*, 2012). These features are oligo/amenorrhea, androgen excess (can be seen by hirsutism), and polycystic ovaries (Umayal *et al.*, 2019).

People who are confirmed to have PCOS commonly associated with insulin resistance (50-70%), endometrial hyperplasia (35%) that 5-3 times could occur endometrial cancer, recurrent pregnancy loss (36-56%), obesity, and future metabolic disease. Polycystic ovary syndrome have been regarded as a chronic systemic disease rather than a simple local disease, and it was often associated with chronic inflammation and oxidative stress (OS), although the pathogenesis has not been well defined (Umayal *et al.*, 2019; Homburg, 2008).

Reactive Oxygen Species (ROS) that are found higher in PCOS' women because of oxidative stress,

could induce the release of inflammatory factors and inflammatory responses through the activation of nuclear factor- κ B (NF- κ B), activated protein-1, and hypoxia-inducible factor-1. Further oxidative stress with inflammation could induce insulin resistance through post-insulin receptor signaling pathway that is insulin receptor substrate 1-phosphatidylinositol 3 kinase-protein kinase B pathways (Touyz, 2005).

Insulin resistance will increase the frequency of GnRH and the pulsation of LH secretion. Because of this, there will be a compensation of hyperinsulinemia and also ovaries will lead to excess the production of androgen (Rojas *et al.*, 2014). Then, ovarian theca androgen production will increase and production of SHBG by the liver decrease due to hyperinsulinemia (Azziz *et al.*, 2009).

In both mouse and human, normal androgen production of theca cells maintains follicular growth via promotion of early-stage folliculogenesis and prevention of follicular atresia. So, androgen excess will lead to abnormal follicular growth and infertility (Ma *et al.*, 2017). Patients with syndromes of severe insulin resistance often demonstrate ovarian hyperthecosis, a pathologic finding characterized by islands of hyperplastic luteinized theca cells located throughout the stroma and the presence of relatively few and small atretic follicles (Azziz *et al.*, 2009).

Untill now, the treatment of PCOS obese patients is done by giving metformin as the first line drug. Metformin plays role in controlling glucose blood level. It can delay the absorption of hepatic glucose, make an increasement in the uptake of peripheral glucose, lower the level of peripheral insulin, and also improve the GLUT-4. In the other hand, giving metformin for long-term use can cause some side effects, such as: indigestion, diarrhea, and others (Huang *et al.*, 2015). Because of this reasons, long-term treatment for PCOS using metformin isn't suitable.

The search for herbs that have potential capabilities as preventative and scientifically proven could be used for treatment alternative a much-needed. *Moringa oleifera* (drumstick tree, horse-radish tree, miracle tree) was known in Indonesia as one of the plants that contain anti-oxidants. Phytochemical studies of the *Moringa oleifera* plant that revealed large polyphenols such as quercetin glucoside, routine, kaempferol glycoside, and chlorogenic acid in *Moringa oleifera* flour via high performance liquid chromatography (HPLC) analysis (Johnson, 2005). Quercetin exhibits activity as an anti-oxidant by decreasing lipid peroxidation (MDA) and increasing anti-oxidant enzyme activity in STZ-induced diabetic-induced mouse mellitus (Adewole *et al.*, 2007).

In this study, we aimed to determine that giving *Moringa oleifera* leaf extract as an anti-oxidant could decrease the follicle repair in PCOS with insulin resistance. This plant was an original plant in various Asian countries, abundant and cheap as a food source. Thus, every health benefit of this plant will reach most of the population.

MATERIALS AND METHODS

Plant Material

Moringa oleifera commonly referred as the miracle tree that was a family of Moringaceae originating from Southern Asia. The leaves of this tree are rich in minerals, vitamins and other important phytochemicals (Sujatha and Patel, 2017). *Moringa oleifera* extract (Kelorina, Moringa Indonesia, Blora, Indonesia) in powder form, all the process was done according to standard to obtain *Moringa oleifera* extract. The *Moringa oleifera* leaf was also used in several studies to determine its effectiveness in chronic hyperglycemia and dyslipidemia (Mbikay, 2012).

Animals and Experimental Protocol

This study has received ethical clearance approval number 705-KE by Faculty of Veterinary Medicine Universitas Airlangga. This was a laboratory experimental research using animal model. The female rats of *Rattus norvegicus* strain Wistar (Biochemistry Laboratory, Faculty of Medicine, Airlangga University, Surabaya, Indonesia) were 3 months old and weighed about 100-130 g. These rats were also used as animal models in research of diabetes (Purwanto, Sudiana, Herawati, and Aksono, 2013). Before the study began, there was a week period of adaptation to maintain the rats' health and behavior and resulting in normal vaginal swab. Rats with anatomical abnormalities and pregnant

were excluded. Procedures used in this study had been approved by the ethics committee of the Faculty of Veterinary Medicine of Airlangga University.

Treatment Protocol

The white Wistar strain female rats (*Rattus norvegicus*) of 40 samples were divided into 5 groups randomly (n= 8), which were: negative control group (K1), positive control group (K2), and treatment groups (K3, K4, K5). Negative control group (K1) was only given aquades, while the other four groups were PCOS model. Preparation of PCOS with insulin resistance model was done by using testosterone propionate injection (Testohormon, Wonderindo Pharmatama, Jakarta, Indonesia). This PCOS model was done based on previous research by Susanto *et al.* (2012). This hormone was given intramuscularly in the thigh with a dose of 1 mg/100 g BW once a day for 28 days until PCOS-resistance insulin model obtained. Furthermore, the positive control group was (K2) given aquades only, the third group (K3) was followed by giving metformin therapy (2 mg/100 g BW, orally), the fourth and fifth group followed by giving *Moringa oleifera* extract orally (250 mg/kg BW for K4) and (500 mg/kg BW for K5) for 14 days. Before and after the study period, vaginal swab were done to know what cycle was ongoing before and after the study. Before the animal was sacrificed, it has fasted for 12 hours and then ovarium removal was done to measure the thickness of the theca cell.

Estimation of Histological Parameters

The thickness of theca cells follicle was examined by hematoxylin-eosin staining (HE) (Susanto *et al.*, 2012). Later on, HE was a colouring method widely used in tissue staining, aiming to make it easier to see changes in the tissue. The preparation of ovarium organs was coloured with a hematoxylin-eosin dye, so it could be clearly seen the shape of each cell. The coloured tissue was then placed on object glass which was covered with cover glass that has been previously spilled with entellan, then the tissue was observed under a microscope.

Data Analysis

The data were subjected to one way analysis of variance (ANOVA) using SPSS statistical software version 24.0 (SPSS, Inc., Chicago, IL).

RESULTS AND DISCUSSION

We conducted vaginal swab examination before and after the treatment. Vaginal swab before treatment showed that most female rats in all groups were in the estrous phase, none of which were in the diestrus phase (Figure 1). This vaginal swab was done to ensure that all female rats were in estrous phase before treatment so we could conclude that all the animals were in normal reproductive phase. The results of the vaginal swab after treatment showed that there was a diestrus phase in the group receiving 1 mg/100 g BW injection treatment intramuscular for 28 days (Figure 2). This

result showed that the injection of testosterone propionate could arrest the estrous cycle in diestrous phase (Nallathambi and Bhargavan, 2019).

The results of measurements of theca cell thickness on ovary samples of control female rats and treated groups using the HE method (Figure 3) showed that the PCOS control group had higher cell-density cells than the other groups. The group treated with the leaf extract

of *Moringa oleifera* at the dose of 500 mg/kg BW had a lower theca cell thickness than the other group (Figure 3). Metformin and *Moringa oleifera* leaf extracts showed the significant decrease in the thickness of theca cell ($P<0.05$) compared to the PCOS-insulin resistance control group (Table 1).

The PCOS model in this study increased the thickness of the theca cell. The thickness of theca cell

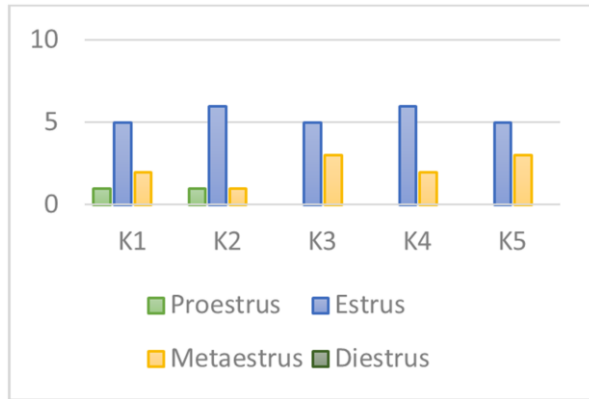


Figure 1. Graph of vaginal swab data of the experimental unit before treatment. The results of the vaginal swab in the experimental unit before treatment showed that most of the female rat in all groups were in the estrous phase, none of which was in the diestrous phase

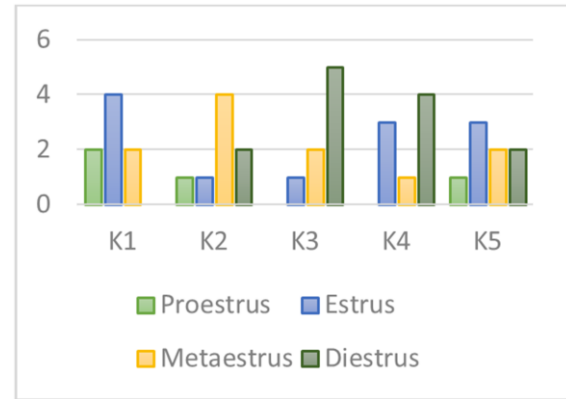


Figure 2. Graph of vaginal swab data of the experimental unit after treatment. The results of vaginal swab after treatment showed that there was a diestrous phase in the group treated with injection of testosterone propionate for 28 days (K2, K3, K4, and K5)

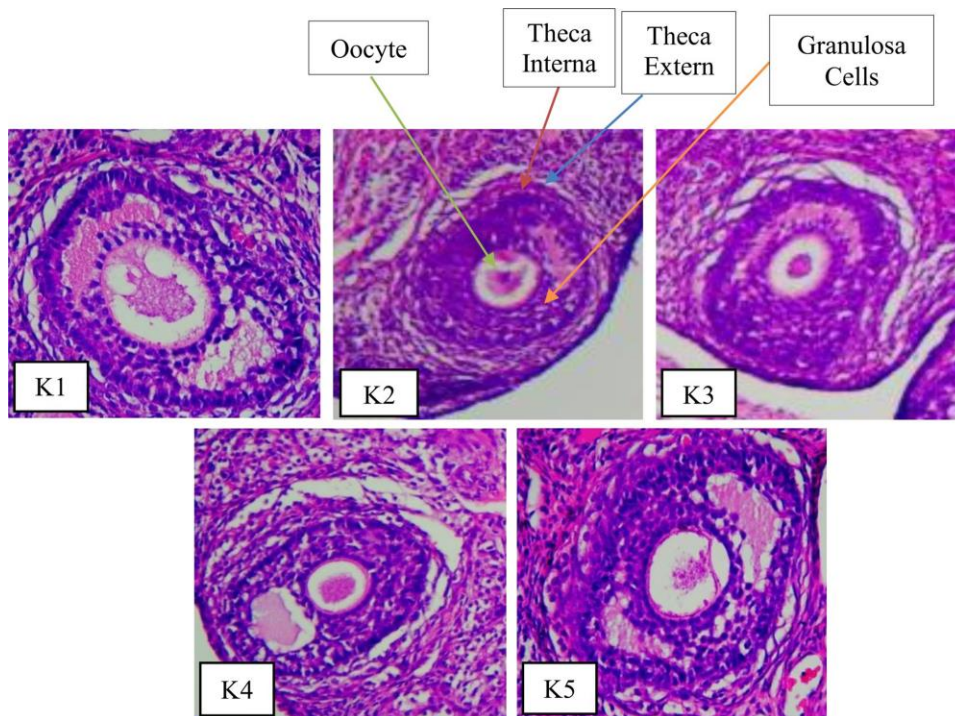


Figure 3. Follicle theca cell thickness of PCOS model (in μm). The highest covariate cell thickness was obtained in group 2 (PCOS insulin resistance control group), whereas the lowest cell thickness was obtained in group 5 (PCOS insulin resistance with *Moringa oleifera* leaf extract 500 mg/kg BW group)

Tabel 1. Effect of treatment on histological parameters

Sample	Group				
	K1	K2	K3	K4	K5
Theca cell thickness	1.573±0.551	0.000±.000*	1.950±0.577**	2.187±0.860**	0.931±0.457**

*Significantly different from normal control ($P<0.05$), ** significantly different from PCOS control-insulin resistance ($P<0.05$), K1= Negative control group; K2= Positive control group; K3= PCOS insulin resistance metformin group; K4= PCOS insulin resistance *Moringa oleifera* leaf extract 250 mg/kg BW group; K5= PCOS insulin resistance *Moringa oleifera* leaf extract 500 mg/kg BW group

was measured under microscope. The PCOS control group significantly increased the thickness of the theca cells compared with the normal control group. Provision of testosterone propionate of 1 mg/g BW in female rats in this study for 28 days was able to increase tertiary theca cell thickness (7.77 μm) in PCOS control group compared to tertiary theca cell thickness (5.77 μm) of the normal control group).

Women with PCOS syndrome usually have an enlarged ovary with an increased number of follicles and volume of the stroma. The treatment of high-dose androgens causes suppression of gonadotropin, but their ovaries were not depressed but enlarged by the increasing number of "cystic" follicles and theca-interstitial hyperplasia, meeting the PCOS morphology criteria. These observations show that androgens could cause growth of ovarian and theca-interstitial follicles (Vendola *et al.*, 1998). The previous studies whose using rat that was given testosterone injections for 28 days also showed a change in ovarian morphology including the presence of thickening of theca cells (Wu *et al.*, 2014).

The *Moringa oleifera* extract could decrease the thickness of theca cells follicles in the PCOS model. The thickness of the tertiary theca cell follicles given *Moringa oleifera* leaf extract at doses of 250 mg/kg BW and 500 mg/kg BW, as well as the metformin group, significantly decreased the thickness of the theca cells compared to the PCOS group.

Additionally, giving *Moringa oleifera* leaf extract on a female mouse model of PCOS as anti-oxidant could decrease oxidative stress level. The reduction of oxidative stress might inhibit the release of inflammatory factors and the inflammatory response by inhibiting the activation of nuclear factor-kB, activated protein-1 and hypoxia-inducible factor-1 (Touyz, 2005). The decrease in inflammation might decrease induction of insulin resistance through post-insulin receptor signaling the pathway and the insulin receptor of substrate 1-phosphatidylinositol 3 kinase-protein kinase B pathways. Since the peripheral tissue's resistance of insulin decreased, the production of androgen in ovaries will also decrease. Moreover, lower level of insulin and IGF-1 could lead to the increasing of SHBG production indirectly, thus it would lower the androgen levels. The decline of androgen level will affect the ovarium's environment and contribute to the morphological changes of ovaries (Rojas *et al.*, 2014).

Furthermore, the drumstick tree was a rich plant in nutrients as well as macro, micronutrients, minerals, and vitamins. The nutrient content of the powder of the drumstick tree leaf was vitamin A 16.3 mg/100 g, vitamin C 17.3 mg/100 g, vitamin E 113.6 mg/100 g, flavonoid 473.3 mg/g also selenium 0.9 μg /100 g. Vitamin E was the most important fat-soluble anti-oxidant and protects against lipid membranes from oxidative damage. Vitamin E has a major function as a fat-soluble anti-oxidant and it was easy to provide hydrogen from the hydroxyl (OH) groups in the ring structure to free radicals. Vitamin E improves the

potential for free radical defense systems and has a beneficial effect in the improvement of glucose transport and insulin sensitivity. Previous research conducted by Rzepczynska *et al.* (2011) proves that administration of anti-oxidants (vitamin E) could improve the theca cell in rats induced by 17 β estradiol.

Phytochemical studies of *Moringa oleifera* plants reveal large polyphenols such as quercetin, glucoside, rutin, kaempferol glycoside, and chlorogenic acid in *Moringa oleifera* flour via HPLC analysis (Johnson, 2005). Quercetin is one kind of flavonoid that has an anti-oxidant effect. Quercetin and its glycosides are the largest flavonoid group, which built about 60-75% of flavonoid. Flavonoid anti-oxidants limit the negative effects of free radicals through the quick transfer of hydrogen atoms to the radicals. The predominance of quercetin in preventing both metal and non-metal-induced oxidative damage is partly attributed to its free 3-OH substituent which is believed to increase the stability of the flavonoid radical (Alrawaiq and Abdullah, 2014). Study of anti-oxidant effects (rutin flavonoids) in PCOS showed that there was an improvement in theca cell and oxidative stress cells in letrozole-induced rat (Jahan *et al.*, 2016).

CONCLUSION

Moringa oleifera leaf extract as an anti-oxidant proven to decrease the thickness of theca cell of the female rat model of PCOS.

REFERENCES

- Adewole, S.O., E.A. Caxton-Martins, and J.A. Ojewole. 2007. Protective effect of quercetin on the morphology of pancreatic β -cells of streptozotocin-treated diabetic rats. **Afr. J. Tradit. Complem.** 4(1):64-74.
- Alrawaiq, N. Salem, and A. Abdullah. 2014. A review of flavonoid quercetin: Metabolism, bioactivity and antioxidant properties. **Int. J. Pharm. Tech. Res.** 6(3):933-941.
- Azziz, R., E. Carmina, D. Dewailly, E. Diamanti-Kandarakis, H.F. Escobar-Morreale, and W. Futterweit. 2009. The androgen excess and PCOS society criteria for the polycystic ovary syndrome: the complete task force report. **Fertil. Steril.** 91(2):456-488.
- Fausser, B.C., B.C. Tarlatzis, and R.W. Rebar. 2012. Consensus on women's health aspects of polycystic ovary syndrome (PCOS): The Amsterdam ESHRE/ASRM-Sponsored 3rd PCOS consensus workshop group. **Fertil. Steril.** 97(1):28-38.
- Homburg, R. 2008. Polycystic ovary syndrome. **Best Prac. Res. Clin. Ob.** 22(2):261-274.
- Huang, Y., J. Sun, X. Wang, X. Tao, H. Wang, and W. Tan. 2015. Asymptomatic chronic gastritis decreases metformin tolerance in patients with type 2 diabetes. **J. Clin. Pharm. Ther.** 40(4):461-465.
- Jahan, S., F. Munir, and S. Razak. 2016. Ameliorative effects of rutin against metabolic, biochemical and hormonal disturbances in polycystic ovary syndrome in rats. **J. Ovarian Res.** Doi: 10.1186/s13048-016-0295-y.
- Johnson B. 2005. Clinical perspectives on the health effects of *Moringa oleifera*: A promising adjunct for balanced nutrition and better health. **KOS Health Publications.**
- Ma, Y., S. Andrisse, Y. Chen, S. Childress, P. Xue, and Z. Wang. 2017. Androgen receptor in the ovary theca cells plays a critical role in androgen-induced reproductive dysfunction. **Endocrinology.** 158(1):98-108.
- Mbikay, M. 2012. Therapeutic potential of *Moringa oleifera* leaves in chronic hyperglycemia and dyslipidemia: A review. **Front. Pharmacol.** 3:24. Doi: 10.3389/fphar.2012.00024.

- Nallathambi, Anandaramajayan, and R. Bhargavan. 2019. Regulation of estrous cycle by *Cynodon dactylon* in letrozole induced polycystic ovarian syndrome in Wistars albino rats. **Anat. Cell Biol.** 52:511-517.
- Purwanto, B., I.K. Sudiana, L. Herawati, and B. Aksono. 2013. Muscle glucose transporter 1 (glut-1) expression in diabetic rat models. **Folia Medica Indonesiana.** 49(1):21-5.
- Rojas, J., M. Chávez, and L. Olivar. 2014. Polycystic ovary syndrome, insulin resistance, and obesity: navigating the pathophysiologic labyrinth. **Int. J. Reprod. Med.** Doi: 10.1155/2014/719050.
- Rzeczczynska, I.J., N. Foyouzi, P.C. Piotrowski, C. Celik-Ozenci, A. Cress, and A.J. Duleba. 2011. Antioxidants induce apoptosis of rat ovarian theca-interstitial cells. **Biol. Reprod.** 84(1):162-166.
- Sujatha, B. and P. Patel. 2017. *Moringa oleifera*-Nature's gold. **Imp. J. Interdiscip. Res.** 3(5):1175-1179.
- Susanto, E., B. Santoso, Samsulhadi, and Widjiati. 2012. Korelasi jumlah ekspresi reseptor IGF-I (Insulin Like Growth Factor-I) dan kelenjar endometrium *Rattus norvegicus* strain Wistar model SOPK (sindroma ovarium polikistik) yang mendapat testosteron. **Majalah Obstet. Ginekol.** 20(2):51-57.
- Touyz, R.M. 2005. Molecular and cellular mechanisms in vascular injury in hypertension: role of angiotensin II—editorial review. **Curr. Opin. Nephrol. Hy.** 14(2):125-131.
- Umayal, B., S.N. Jayakody, N.V. Chandrasekharan, W.S. Wijesundera, and C.N. Wijeyaratne. 2019. Polycystic ovary syndrome (PCOS) and kisspeptin-A Sri Lankan study. **J. Postgrad. Med.** 65:18-23.
- Vendola, K.A., J. Zhou, O.O. Adesanya, S.J. Weil, and C.A. Bondy. 1998. Androgens stimulate early stages of follicular growth in the primate ovary. **J. Clin. Invest.** 101(12):2622-2629.
- Wu, C., F. Lin, S. Qiu, and Z. Jiang. 2014. The characterization of obese polycystic ovary syndrome rat model suitable for exercise intervention. **PloS One.** 9(6):e99155. Doi:10.1371/journal.pone.0099155.