

THE EFFECT OF AGE ON WOUND HEALING AND PHYSICAL DEVELOPMENT OF LOCAL CATS (*Felis catus*) POST-OVARIOHYSTERECTOMY SURGERY

Renji Mailisa Wahyuni^{1*}, Gunanti², and Deni Noviana²

¹Postgraduate Program in Animal Biomedical Sciences, Department of Pathology and Reproductive Clinics, Faculty of Veterinary Medicine, IPB University, Bogor, Indonesia

²Department of Pathology and Reproduction Clinic, Faculty of Veterinary Medicine, IPB University, Bogor, Indonesia

*Corresponding author: renjimailisawahyuni@gmail.com

ABSTRACT

The purpose of this study was to evaluate the effect of age on wound healing and physical development of local cats (*Felis catus*) after ovariohysterectomy. A total of 15 female cats were divided into three age groups (2-4, 5-9, and 10 months old) with each group consisting of five cats. The treatment group was sterilized using the lateral flank ovariohysterectomy method. Observations of surgical procedures and physical conditions were carried out during anesthesia, including onset, duration of anesthesia and surgery, body temperature, heart rate, and respiratory rate. Post-operative observations were made to evaluate wound healing, hematological profile (RBC, Hb, PCV, WBC, PLT), body weight, Body Condition Score (BCS), bone density, and growth plate closure. The results showed that there was no significant difference ($P>0.05$) during anesthesia, wound healing, or an increase in body weight, BCS, and bone density in all age groups. Ovariohysterectomy at 2-4 months old delayed the closure of the bone growth plates ($P<0.05$). Ovariohysterectomy in pubertal and post-pubertal cats is safe to perform as long as good surgical preparation is provided.

Key words: *Felis catus*, ovariohysterectomy, physical development, wound healing

ABSTRAK

Tujuan dari penelitian ini adalah untuk mengevaluasi pengaruh umur terhadap penyembuhan luka dan perkembangan fisik kucing lokal (*Felis catus*) pasca ovariohisterektomi. Sebanyak 15 ekor kucing betina dibagi menjadi tiga kelompok umur (2-4, 5-9, dan 10 bulan) dengan masing-masing kelompok terdiri atas lima ekor kucing. Kelompok perlakuan disterilisasi dengan metode lateral flank ovariohisterektomi. Pengamatan prosedur pembedahan dan kondisi fisik dilakukan selama anestesi, meliputi onset, durasi anestesi dan operasi, suhu tubuh, frekuensi jantung, dan frekuensi respirasi. Pengamatan pascaoperasi yang dilakukan adalah evaluasi penyembuhan luka, profil hematologi (RBC, Hb, PCV, WBC, PLT), bobot badan, body condition score (BCS), kepadatan tulang dan penutupan lempeng pertumbuhan. Hasil penelitian menunjukkan tidak ada perbedaan signifikan ($P>0,05$) selama anestesi, penyembuhan luka, peningkatan bobot badan, BCS, dan kepadatan tulang pada semua kelompok umur. Ovariohisterektomi pada umur 2-4 bulan dapat menunda penutupan lempeng pertumbuhan tulang ($P<0,05$). Ovariohisterektomi pada kucing prapubertas dan pascapubertas aman dilakukan selama persiapan pembedahan yang baik terpenuhi.

Kata kunci: *Felis catus*, ovariohisterektomi, perkembangan fisik, penyembuhan luka

INTRODUCTION

Ovariohysterectomy is the most commonly recommended medical procedure in female cats for population control, prevention of reproductive hormones, and increasing cats' survival (Adams 2020). Ovariohysterectomy in cats has been performed at all ages. Five to eight months old is the most common age range chosen by veterinarians for ovariohysterectomy (Joyce and Yates 2011). Ovariohysterectomy operations on cats have also been performed at pubertal and young ages by veterinary practitioners in several countries. Ovariohysterectomy in cats aged 5-8 months is considered to support one of the ovariohysterectomy's goals, namely controlling the overpopulation problem because cats at this age range enter puberty, and unwanted pregnancies occur before ovariohysterectomy (Bender 2012).

The benefits of performing ovariohysterectomy in young cats before the first estrous period are fast recovery from anesthesia and fast wound healing (Kustritz 2002). Several studies reported that ovariohysterectomy surgical procedures in young cats are safe; however, veterinarians remain concerned about the long-term health risks, including infectious diseases in ovariohysterectomy cats (Porters *et al.* 2014).

Veterinarians' concerns about pubertal and young ovariohysterectomy arise because of the risks posed by surgical and anesthetic procedures at the pubertal (pediatric) age. Veterinarians are also concerned about early estrogen deficiency which is thought to affect the balance of metabolism, causing disorders, such as orthopedic disorders, obesity, long bone growth and delayed physical development, immune suppression, and behavioral disorders (Howe 2015).

The increased risk of complications and the benefits of ovariohysterectomy in cats are assumed to be influenced by several individual factors, such as age, body size, and race (Howe 2015). Indonesia currently does not have recommendations or standards regarding the determinations and appropriate age of female cats to undergo ovariohysterectomy surgery, and there are only a few studies that support ovariohysterectomy for local cats at a certain age. This study aimed to investigate the effect of age on wound healing and the physical development of local cats (*Felis catus*) after undergoing ovariohysterectomy surgery.

MATERIALS AND METHODS

This research was conducted from November 2021 to June 2022 at the Terra Veterinary Practice Clinic,

Gading Serpong, Tangerang Regency, Banten. All procedures carried out in this study were approved by the Ethics Commission for Experimental Animals of the National Research and Innovation Agency (BRIN) with certificate number 015/KE.02/SK/6/2022. This experimental research used 15 local female cats based on the method of calculating the number of animal samples by Arifin and Zahiruddin (2017). The cats used were in good health based on the results of the clinical examination. The cats were divided into three surgical treatment groups based on age categories (2-4, 5-9, and ≥ 10 months), with each treatment group consisting of five cats. All of them were acclimatized for two weeks and underwent a physical examination before surgery.

Before administering anesthesia, cats aged 2-4 months fasted for 2-4 hours; cats aged 5-9 and ≥ 10 months fasted for 8-12 hours. All treatment groups were premeditated with atropine sulfate of 0.25 mg/mL for 10-15 minutes before the subcutaneous induction of anesthesia at a dose of 0.02 mg/kg BW. The cats were anesthetized using a mixture of 10% ketamine at a dose of 10 mg/kg BW and 2% xylazine at a dose of 1 mg/kg BW intramuscularly. Some measurements in terms of heart rate, respiratory rate, body temperature, onset, and duration of anesthesia were performed on the anesthetized cats until they were conscious.

Surgery was performed using the lateral flank ovariohysterectomy method. After the operation, the cats were given wound care, and an evaluation of wound healing was carried out. Body weight measurements were carried out every week until the end of the study (24 weeks or 6 months postoperative). Radiographic examinations were performed pre-operative and six months post-operative for ovariohysterectomy. The cats were fed commercial cat feed twice a day and water *ad libitum*.

Ovariohysterectomy Surgery

The ovariohysterectomy surgical procedure was performed using the lateral flank ovariohysterectomy method (Fossum *et al.* 2013). The cats were placed on the operating table in the lateral incumbency position; the hind legs were straightened, and the right side of the abdomen was prepared as the operation area. Hair in the surgical area was shaved and disinfected using 70% alcohol and 3% iodine tincture. A sterile dressing was placed over the lateral area of the abdomen to reduce contamination from the surrounding environment. The incision was made in the orientation area, namely on the flank with the upper limit position of 2 cm from the lumbar and cranial transverse processes, 1-2 cm from the last rib with an incision length of 2-3 cm in the vertical direction. The incision was made to the skin subcutaneously, fatty tissue, muscle (external obliques abdominal and internal obliques abdominal muscles), fascia, and peritoneum. In an incision in the muscle, it is necessary to pay attention to the blood vessels around the muscle area. If there are blood vessels that are cut and bleeding and ligate the blood vessels that are cut and bleeding

occurs, clamp the source of the bleeding and ligate the blood vessels properly to stop the bleeding. After opening the abdominal cavity, explore the uterus using the index finger or ovariohysterectomy hook along the abdominal wall. The index finger or ovariohysterectomy hook was turned medially to capture the left uterine horn and its ligaments. The uterine horn and its ligaments were removed from the abdominal cavity and traced until the uterine and ovarian bifurcations were identified.

The left ovarian suspensory ligament close to the kidney was cut without tearing the ovarian vessels for exteriorization of the ovary. The mesovarium in the broad caudal ligament was perforated to approach the ovarian ligament. The ligaments of the left ovary were clamped using two to three hemostats in a position under the blood vessels and ligated between the hemostats using catgut 3/0 chromic threads for two ties. The ligated ovarian ligaments were excised and evaluated. The hemostat clamping the ligated ovarian ligaments was released. Identify the right uterine body and trace the bifurcation in a cranial and lateral direction until locating the ovary. Pinching, ligation, and cutting of the ligament of the right ovary were carried out in the same way as the previous procedure. Both ovaries that had been cut were removed to get the corpus uteri. The corpus uteri were clamped using two hemostats and ligated between the hemostats using catgut 3/0 chromic threads with two ties. The ligated uterine corpus was excised and evaluated.

The remaining pieces of the uterus and omentum were repositioned into the abdomen. The peritoneum was closed with a simple interrupted suture pattern using a 3/0 chromic catgut suture. The muscle was closed with a simple continuous suture pattern using a 3/0 chromic catgut suture. The skin was closed with simple interrupted sutures using 3/0 silk thread. During the wound closure procedure using stitches, the wound was cleaned with physiological NaCl and given antibiotics, and scars on the skin were given 3% iodine tincture and closed with bandages.

Wound Healing

Postoperative skin wound healing was evaluated clinically on the 1st, 3rd, 5th, 7th, 9th, 11th, 13th, and 14th postoperative days. The postoperative skin wound healing scoring system was evaluated using a scoring score of 0-5 adopted by Otter *et al.* (2018). Wounds were evaluated based on clinical findings using a score of zero to a score of five. Score 0= wound healing was complete, wound edges were in position, and the wound was tightly closed; Score 1= mild redness of the skin around the wound or incision edges, no open wounds; Score 2= swelling, redness, discharged from an open wound or subcutis; Score 3= partial open wound of the skin and exposure of the subcutaneous layer or muscle (re-suture and further clinical treatment required); Score 4= complete open wound of skin and Subcutaneous tissue; Score 5= complete open wound in all three layers (emergency care required). Cats were given oral antibiotics amoxicillin at a dose of 10 mg/kg

BW twice a day for 5 days, anti-inflammatory meloxicam orally at a dose of 0.1 mg/kg BW once a day for 5 days, vitamins C and B complex orally at a dose 50 mg/head twice a day for 5 days. Thread retrieval was carried out on the 5th day after the ovariohysterectomy operation. The postoperative wound was cleaned, the topical antibiotic gentamicin was applied once a day for 7 days, and the wound dressing was changed regularly once a day for seven days.

Retrieval and Examination of Bone Radiography

The cats were placed on a special table for radiographic examination in the dorsal Recumbency position using a Kilo Voltage Peak (kVp) setting of 48 and milliamperere second (mAs) 10. Bone radio graphic examination was carried out preoperative and 6 months postoperative. The radiographic images taken were in the form of growth and bone density in the cats' long bones. Bone growth was evaluated based on the closing time of the bone growth plates and the assessment of bone density was evaluated based on the trabecular pattern using the Singh Index method (Jang *et al.* 2021). The degree of trabecular pattern change includes score 6= all trabecular groups were visible; Score 5= secondary compression trabecular group was not visible; Score 4= the secondary compression trabecular group had disappeared; Score 3= the tensile trabecula was only clearly visible at the top of the femoral neck; Score 2= only primary compressed trabecula were visible; Score 1= the number of primary compression trabecula was greatly reduced and unclear.

Blood Check

Blood samples from the treatment and control groups were taken from the *dorsal antebrachial cephalic* vein and put into a vacuum tube blood with Ethylene Diamine Tetra Acetic Acid (EDTA) anticoagulant. Blood tests were carried out on days 0, 1, 5, and 7 after the ovariohysterectomy operation. Blood profile examination, including Hemoglobin (Hb), Packed Cell Volume (PCV), Red Blood Cell Count (RBC), White Blood Cell Count (WBC), and Platelets (PLT). For wound healing, it was performed using an automatic hematology analyzer calculating machine.

Body Weight Measurement

Body weight measurement was carried out every week on the same day until the end of the study. All cats were weighed using a digital balance and Body Condition Score (BCS) was determined. Evaluation of the cats' BCS using a nine-point assessment based on Teixeira *et al.* (2020), namely an assessment of the body condition of cats ranging from a score of one (very thin) to a score of nine (very fat). The nine-point BCS examination was performed by evaluating the ribs, spine, waist, and body fat. Score 1= the short-haired cat's ribs were clearly visible; no fat was felt; there was severe abdominal compression, and the lumbar vertebrae and ilium bones were clearly visible

and easily palpable. Score 2= ribs in a short-haired cat were clearly visible, and there was a pronounced twitching of the abdomen and no palpable fat. Score 3= the ribs were easily palpable with a little layer of fat, the lumbar vertebrae and waist behind the ribs were clearly visible, and there was little abdominal fat. Score 4= palpable ribs with little layer of fat, loin visible behind ribs, few abdominal folds, and no abdominal fat pads. Score 5= was a proportional BCS, palpable ribs with little fat, visible waist behind the ribs, and there was little abdominal fat padding. Score 6= palpable ribs with little excess fat, loin and abdominal fat pads can be distinguished but not clearly defined, and no abdominal tightening was found; Score 7= the ribs were not easily palpable with a moderate layer of fat, the rounding of the abdomen was clearly visible, the waist cannot be moved properly, and there was a moderate amount of abdominal fat pads; Score 8= the ribs were not palpable with excess fat layer, the waist was not visible, there was a clear rounding of the abdomen with protruding abdominal fat pads, and there were deposits of fat in the waist area. Score 9= ribs were not palpable with a thick layer of fat; there was abdominal distention without waist, severe fat deposits on the waist, face, limbs, as well as visible extensive abdominal fat deposits.

Data Analysis

Research variable data were analyzed statistically using the one-way analysis of variance (ANOVA) method, the Chi-square test, the Kruskal-Wallis, and paired T-Test, at a 95% confidence interval.

RESULTS AND DISCUSSION

The mean duration of xylazine ketamine anesthesia in cats that were operated on by ovariohysterectomy in the age group 2-4, 5-9, and ≥ 10 months showed that there was a significant difference with $P < 0.05$, and there were no mean values for the onset of anesthesia and duration of surgery with a significant difference ($P > 0.05$). The duration of anesthesia for cats aged 2-4 months was shorter than for those aged 5-9 months and ≥ 10 months. The maximum effect of anesthesia (duration of anesthesia) of the ketamine xylazine combination in cats lasted 30-45 minutes, and full recovery took 8-12 hours, depending on the dose given (El-Sherif 2018).

The onset of anesthesia in cats undergoing ovariohysterectomy at ages of 2-4, 5-9, and ≥ 10 months was rapid and no adverse symptoms appeared. All cats were calmly anesthetized, no vomiting occurred, and good muscle relaxation was produced. All cats in the age group were anesthetized (onset) in about 2-3 minutes and showed signs of decreased consciousness and muscle relaxation. The average onset of xylazine ketamine Anesthesia in domestic cats was 3.33 ± 2.07 minutes intramuscularly (Rahmiati and Wira 2019). The duration of the ovariohysterectomy operation in all age groups lasted about 15-16 minutes. The operation time was shorter than the ovariohysterectomy performed by Kiani

et al. (2014). Ovariohysterectomy in adult female cats took about 28.3 ± 11.7 minutes and 24.6 minutes using the incision method in the pelvic area. The average values of onset, anesthetic duration, and duration of ovariohysterectomy surgery in local female cats aged 2-4, 5-9 and ≥ 10 months can be seen in Table 1.

The mean values of body temperature, heart rate (beats/minute), and respiration frequency (beats/minute) of cats anesthetized with ketamine xylazine in cats and from the age groups of 2-4, 5-9 and ≥ 10 months showed no significant difference ($P > 0.05$). The average body temperature of cats anesthetized with xylazine ketamine for ovariohysterectomy decreased every 15 minutes up to 45 minutes after induction and experienced an increase in temperature after 60 minutes of induction (Figure 1). The average body temperature of cats in the three age groups was normal when they were anesthetized until they recovered from the anesthesia effects. The normal temperature value for a cat under anesthesia is $37.8-36.1^\circ\text{C}$ (Thomas and Lerche 2017) or $36.6-35.5^\circ\text{C}$ (Shelby and McKune 2014), and the critical temperature value that can cause adverse effects such as Hypothermia the body was $< 34.0^\circ\text{C}$ (Redondo *et al.* 2012).

The average value of heart rate and respiratory frequency in all age groups decreased every 15 minutes until 30 minutes of anesthesia. The heart rate increased at 60 minutes and the respiratory rate increased at 45 and 60 minutes after induction (Figure 1). The decrease

and increase in heart rate in the three age groups were still normal. The normal heart rate of a cat under anesthesia is 60-120 beats/minute, 120-180 beats/minute (Thomas and Lerche 2017), or 100-250 beats/minute (Shelby and McKune 2014). The heart rate decreased because the cat lost blood volume during the ovariohysterectomy and the effects of the combination of ketamine xylazine and the increase in heart rate occurred at 45 and 60 minutes due to the disappearing effects of Ketamine. The decrease in respiratory frequency was influenced by the effects of ketamine and xylazine which can depress the respiratory center in the medulla oblongata and pons and reduce respiration frequency (Noviana *et al.* 2006).

Age at ovariohysterectomy was not a risk factor for wound complications, and there was no significant difference ($P > 0.05$) in the development of wound healing after ovariohysterectomy in local female cats aged 2-4, 5-9, and ≥ 10 months was performed. Wound healing after ovariohysterectomy surgery generally occurred on day 5 and all incisions in the three age groups were closed on day 7 (Figure 2).

Wound healing after ovariohysterectomy surgery in the three age groups did not show poor wound healing or complications (Figure 2). Ovariohysterectomy and castration are included in the classification of sterile (clean) surgery with a low surgical complication rate and a wound infection rate of 0.0-4.9% (Otter *et al.* 2018). Begum and Bhuvaneshwari's (2019) study also

Table 1. Average onset value, duration of ketamine xylazine anesthesia, and duration of ovariohysterectomy surgery in local female cats

Age group (months)	Number of animals (cats)	Anesthesia		Operation duration (minutes)
		Onset (minutes)	Duration (minutes)	
2-4	5	2.56 ± 0.35	35.17 ± 2.41^a	15.40 ± 1.14
5-9	5	2.60 ± 0.71	$41.86 \pm .67$	16.80 ± 1.30
≥ 10	5	3.48 ± 1.50	45.62 ± 5.27	16.40 ± 1.14

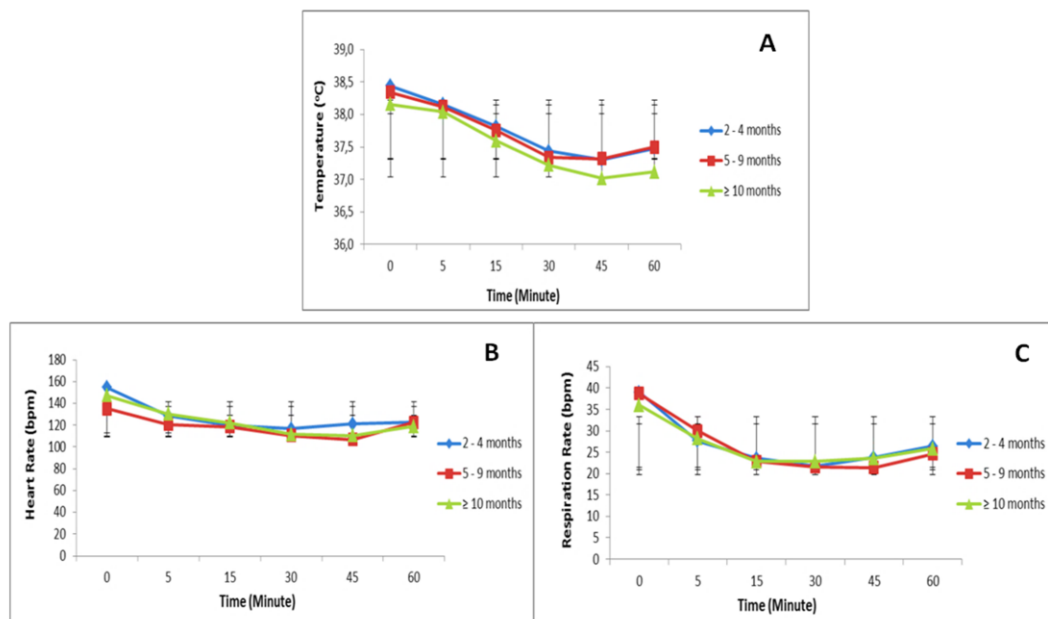


Figure 1. Physiological condition of local female cats aged 2-4, 5-9, and ≥ 10 months induced by ketamine and xylazine anesthesia during the ovariohysterectomy surgery. A= The average value of body temperature ($^\circ\text{C}$); b= The average heart rate (Times/Minute); C= The average value of respiration frequency (times/minute)

showed that the average complete healing of an ovariohysterectomy wound lasted 5-7 days postoperative with a percentage (%) of postoperative wound complications of 0.05 ± 0.02 in ovariohysterectomy surgery with single ligation (one) and 0.11 ± 0.03 in the group that was ligated with two bundles of ovarian ligaments and uterine corpus.

Hematological evaluation (blood test) of local female cats aged 2-4, 5-9, and ≥ 10 months was carried out preoperative and on days 1, 5, and 7 after ovariohysterectomy. The hematological evaluation included Hb, PCV, RBC, WBC, and PLT. The mean values of preoperative hematological examination for the age group 2-4, 5-9, and ≥ 10 months were within the normal range. Statistical analysis of all postoperative ovariohysterectomy hematological parameters showed no significant difference between the age groups ($P > 0.05$). All age groups experienced the same postoperative changes in hematological values. After the ovariohysterectomy operation, each treatment age group experienced changes in hematological parameters on days 1, 5, and 7 before the ovariohysterectomy surgery. Changes in postoperative ovariohysterectomy hematological values in the age groups of 2-4, 5-9, and ≥ 10 months were still within the normal value range.

The average values of RBC, Hb, and PCV for all age groups on days 1, 5, and 7 after ovariohysterectomy decreased from the preoperative average values. Decreased RBC, Hb, and PCV values can be affected by the administration of anesthesia and blood loss during surgery (Chandrakala et al. 2017). The organ that most often affects the RBC Count during surgery under anesthesia is the spleen. Anesthesia-induced relaxation of the scenic vessels will

lead to a decrease in the concentration of circulating erythrocytes in the peripheral blood (Dhumeaux et al. 2012). The average values of the WBC age groups of 2-4, 5-9, and ≥ 10 months on days 1, 5, and 7 after ovariohysterectomy surgery experienced an increase from the preoperative average value. A temporary increase in WBC is the result of an increase in the Hormone Cortisol triggered by stress, anesthetic drugs, surgical trauma, and postoperative care (Zlateva and Marinov 2015).

The surgical stress response during and after surgery involves the organism's physiological reactions to restore homeostasis or to resist a stimulus. Somatic and autonomic afferent nerve impulses generated at the site of surgical trauma activate endocrine responses mediated by stimulation of the sympathoadrenal system and the hypothalamic-pituitary-adrenal axis. At the same time, inflammatory and immune responses begin to develop, mediated by the secreted products of cytokines from activated leukocytes, fibroblasts, and endothelial cells. This compensatory mechanism prevents secondary damage and increases the availability of substrates needed by essential organs and tissue healing involving changes in hematology, metabolism, and immunomodulation (Rubio et al. 2022).

Changes in body weight after ovariohysterectomy in cats aged 2-4, 5-9, and ≥ 10 months showed no significant difference between the treatment groups ($P > 0.05$). Loss of body weight occurred at weeks 1 to 2, and at weeks to 24, there was a significant increase in body weight every week after ovariohysterectomy ($P < 0.05$) (Figure 3). Body weight increased in all age groups after ovariohysterectomy, as noted in the study

Table 2. Average wound healing hematological values of local female cats aged 2-4, 5-9, and ≥ 10 months post-operative ovariohysterectomy on days 1, 5, and 7

Parameter	Unit	Reference range	Age group (months)											
			2-4				5-9				≥ 10			
			0	1	5	7	0	1	5	7	0	1	5	7
WBC	$10^3/\text{mL}$	5,5 - 19,5	13,5 ± 4,83	16,8 ± 6,94	16,3 ± 6,81	15,9 ± 6,73	13,7 ± 3,67	17,9 ± 4,87	17,4 ± 4,76	16,7 ± 4,05	13,2 ± 4,14	17,2 ± 7,07	17,0 ± 6,92	16,2 ± 6,76
			7,3 ± 0,71	6,4 ± 1,60	6,0 ± 2,21	7,7 ± 1,80	7,6 ± 0,74	6,7 ± 2,15	7,8 ± 0,87	6,9 ± 1,16	7,3 ± 0,54	7,6 ± 1,53	6,9 ± 0,99	8,1 ± 0,79
RBC	$10^6/\text{mL}$	4,6 - 10	12,1 ± 1,56	11,7 ± 1,66	10,6 ± 1,98	12,1 ± 2,29	12,3 ± 1,72	10,3 ± 2,13	12,4 ± 1,69	12,4 ± 3,16	11,6 ± 0,97	13,3 ± 3,54	12,4 ± 2,24	12,5 ± 1,52
			36,3 ± 4,10	34,4 ± 4,54	32,8 ± 4,28	34,0 ± 4,17	35,0 ± 5,72	31,1 ± 4,91	36,8 ± 4,22	33,6 ± 4,29	35,3 ± 3,44	36,1 ± 6,85	34,0 ± 3,54	33,6 ± 1,68
PCV	%	28 - 49	213,4 ± 23,23	231,4 ± 95,82	256,6 ± 211,40	317,2 ± 216,10	337,8 ± 199,97	334,0 ± 274,54	244,6 ± 43,81	187,8 ± 223,24	253,2 ± 138,89	219,6 ± 21,79	283,4 ± 97,65	390,4 ± 168,55
PLT	$10^3/\text{mL}$	100 - 514												

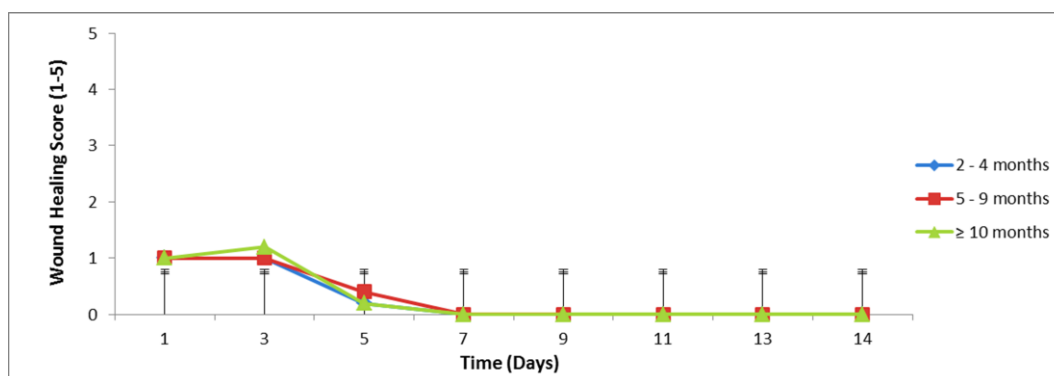


Figure 2. The wound healing time of local female cats aged 2-4, 5-9, and ≥ 10 months after ovariohysterectomy surgery

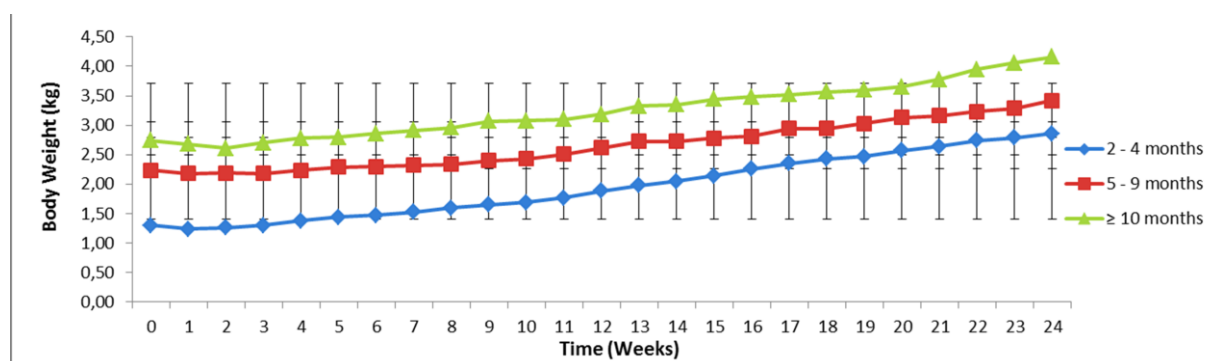


Figure 3. Changes in body weight (Kg) of local female cats aged 2-4, 5-9, and ≥ 10 months postoperative ovariohysterectomy up to 6 months postoperative

Table 2. Changes in bone density in cats aged 2-4, 5-9, and ≥ 10 months preoperative and 6 months post-operative ovariohysterectomy based on trabecular patterns using the Singh index method

Age group (Months)	Before operation	6 Months postoperative
2-4	6 \pm 0.00	6 \pm 0.00
5-9	6 \pm 0.00	6 \pm 0.00
≥ 10	6 \pm 0.00	6 \pm 0.00

Table 3. Long bone growth plate closure in cats aged 2-4, 5-9, and ≥ 10 months after 6 months ovariohysterectomy surgery

Age groups (months)	Number of open plate animals (n)	Number of closed plate animals (n)	P-Value
2-4	5	0	0.143
5-9	3	2	
≥ 10	0	5	

by (Vester *et al.* 2009). Other studies showed that an estimated 20% to 30% reduction in food intake is required to maintain a neutered cat's weight as an adult (Belsito *et al.* 2009). Factors that influence the increase in body weight and BCS after ovariohysterectomy surgery are increased food intake, low metabolic rate, and decreased physical activity (Vester *et al.* 2009).

The increase in cat body weight after ovariohysterectomy surgery can also affect the value of the BCS (Jukes *et al.* 2019). Changes in BCS age groups of 2-4, 5-9, and ≥ 10 months postoperative ovariohysterectomy had a significant difference ($P < 0.05$). The age group of ≥ 10 months old experienced a significant increase in BCS compared to the age groups of 2-4 and 5-9 months old. An increase in BCS in cats after ovariohysterectomy at adulthood was also reported in the study of Harper and Watson (2001). The average increase in BCS of cats undergoing ovariohysterectomy at ages of < 4 , 4-8 and > 8 years old experienced an increase in BCS. Cats that had ovariohysterectomy at the age of 12 months experienced changes in BCS which were not only due to increased food intake, but also possibly due to lower metabolic rate and decreased physical activity (Vester *et al.* 2009).

The results of the analysis of bone density data based on the trabecular *Singh Index* pattern for all age groups showed that there was no significant change in bone density ($P > 0.05$). Hapsari's study (2016) reported that the removal of the reproductive organs performed on male cats (castration) did not affect bone density for up to 3 years postoperative. Significant changes in bone density were found in cats castrated for 5 years.

Hapsari (2016) also said that this might be influenced by the age at which the reproductive organs were removed. The results of bone density evaluation of cats at different age groups showed that the age of the cat at the time of the ovariohysterectomy does not affect the bone density 6 months after the ovariohysterectomy (Table 2).

The closure of the bone growth plate of cats in the 2-4 month old group was significantly delayed compared to the ≥ 10 month age group ($P < 0.05$) (Table 3). Ovariohysterectomy performed at a younger age can delay osteoclast maturation, resulting in delayed closure of the long bone growth plate in the cats. Ovariohysterectomy in cats is a risk factor for late bone growth plate closure because reproductive hormones are also responsible for growth plate closure (Borak *et al.* 2015). Estrogen plays a role in reducing chondrocyte proliferation and accelerating growth plate aging by activating estrogen receptors on growth plates (Thrall and Robertson 2015). There were out of five of the 5 – 9 months age group experiencing delays in the closure of the growth plates (Table 3). Another study also showed that there was no difference in growth plate closure in spayed cats at 7 weeks or 7 months old. The same study reported that ovariohysterectomy significantly inhibited radial physeal closure compared to unswayed female cats (Borak *et al.* 2015).

Ovariohysterectomy performed on cats aged 2-4, 5-9, and ≥ 10 months showed that ovariohysterectomy surgery at a young age or prepuberty was safe and there were no complications that occurred during the ovariohysterectomy procedure and six months after the

surgery. Ovariohysterectomy in cats aged 5-9 and ≥ 10 months are at risk of experiencing uncontrolled weight gain post-surgery; therefore, it is necessary to have good feed management to maintain cats' ideal body weight. Ovariohysterectomy in cats aged 2-4 months can be done provided good surgical preparation is done. The drawback of ovariohysterectomy surgery performed on cats aged 2-4 months is the delay in closing the cats' long bone growth plates six months after ovariohysterectomy surgery. Reproductive hormones, such as estrogen, contribute greatly to the process of bone growth in the process of closing the epiphyses (Thrall and Robertson 2015).

Ovariohysterectomy operations performed on small animals before epiphyseal plate closure can result in excessive growth of long bones and lead to a high prevalence of joint disorders. The percentage of increased risk of joint disorders is likely to be two to four times than that of animals that did not undergo ovariohysterectomy surgery. An increased risk of joint disorders is observed in dogs with ovariohysterectomy, especially those aged 6 months. Several studies of cat ovariohysterectomy surgery before the last physical closure also reported that there was an increased risk of postoperative ovariohysterectomy fractures in the long term (Porters et al. 2014).

CONCLUSION

Ovariohysterectomy operations performed on cats aged 2-4, 5-9, and ≥ 10 months are safe to perform and no complications occur during the surgical procedure and 6 months after surgery as long as proper preparation is carried out. Ovariohysterectomy at 2-4 months old can delay the closure of the cats' long bone growth plates. Ovariohysterectomy at the age of 5-9 and ≥ 10 months old posed a risk of experiencing uncontrolled body weight gain to the cats; hence, it is necessary to have good feed management after ovariohysterectomy surgery.

REFERENCES

- Adams VJ. 2020. Reproduction in dogs part 1: surgical and non-surgical desexing options. *Companion Animal*, 25(7):1-9.
- Arifin WN, Zahiruddin WM. 2017. Sample Size Calculation in Animal Studies Using Resource Equation Approach. *Malaysian Journal of Medical Science*, 24(5):101-105.
- Begum MM, Bhuvaneshwari. 2019. Comparison of post-operative wound healing and surgical complications between single suture and conventional ovariohysterectomy in dogs and cats. *Indian Veterinary Journal*, 96(01):31-33.
- Belsito KR, Vester BM, Keel T, Graves TK, Swanson KS 2009. Impact of ovariohysterectomy and food intake on body composition, physical activity, and adipose gene expression in cats. *Journal of Animal Science*, 87(2):594-602
- Bender WM. 2012. Ovariectomy versus ovariohysterectomy. *The Journal of American Veterinary Medical Association*, 240(6):659-660.
- Borak D, Wunderlin N, Bruckner M, Schwarz G, Klang A. 2015. Slipped capital femoral epiphysis in 17 Maine Coon cats. *Journal of Feline Medicine and Surgery*, Doi:10.1177/1098612x15598551.
- Chandrakala K, Sharma KA, Kumari L, Nath RK, Das S, Sahu RK. 2017. Hemato-Biochemical evaluation of ketamine or butorphanol as analgesic in xylazine and propofol anesthesia in canine ovariohysterectomy. *International Journal of Livestock Research*, 7(1):146-152.
- Dhumeaux MP, Snead EC, Epp TY, Taylor SM, Carr AP, Dickinson RM, Leis ML. 2012. Effects of a standardized anesthetic protocol on hematologic variables in healthy cats. *Journal of Feline Medicine and Surgery*. 14(10):701-705.
- El-Sherif MW. 2018. Clinical Anesthetic, Sedative and Analgesic Effects and Physiological Changes After Xylazine-Ketamine-Tramadol Cocktail Administration in Cats Undergoing Orchiectomy. *Journal of Anesthesia and Surgical Reports*, Doi:10.29011/JASR-105.100005.
- Fossum TW, Dewey CW, Horn CV, Johnson AL, MacPhail CM, Radlinsky MG, Schulz KS Willard MD. 2013. *Small Animal Surgery*. 4th ed. Elsevier. Missouri.
- Hapsari IPM. 2016. Radiology Based Detection of Osteoporosis in Castrated Cat (*Felis catus*). Thesis. Univeritas Airlangga, Surabaya.
- Harper EJ, Stack DM, Watson TDG, Moxham G. 2001. Effects of feeding regimens on bodyweight, composition and condition score in cats following ovariohysterectomy. *Journal of Small Animal Practice*, 42(9):433-438.
- Howe LM. 2015. Current perspective on the optimal age to spay/castrate dogs and cats. *Dovepress Veterinary Medicine: Research and Reports*, 8(6):171-180.
- Jang R, Choi JH, Kim N, Chang JS, Yoon, Kim CH. 2021. Prediction of osteoporosis from simple hip radiography using deep learning algorithm. *Scientific Reports*, 11(199997):1-8.
- Joyce A, Yates D. 2011. Help stop teenage pregnancy: early-age neutering in cats. *Journal of Feline Medicine and Surgery*. 13(1):3-10.
- Jukes A, Lui M, Morton JM, Marshall R, Yeow N, Gunew M. 2019. Associations between increased body condition score, bodyweight, age and breed with urethral obstruction in male castrated cats. *The Veterinary Journal*, 244(1):7-12.
- Kiani FA, Kachiwal AB, Shah MG, Nizamari ZA, Khand FM, Lochi GM, Haseeb, Khokhar AM, Oad A, Ansari MI. 2014. Comparative study on midline and flank approaches for ovariohysterectomy in cats. *Journal of Agriculture and Food Technology*. 4(2):21-31.
- Kustritz MVR. 2002. Early spay-neuter: Clinical considerations. *Clinical Techniques in Small Animal Practice*, 17(3):124-128.
- Noviana D, Gunanti, Jelnatik NRFH. 2006. Pengaruh anestesi terhadap saturasi oksigen (SpO₂) selama operasi ovariohisterektomi kucing. *Jurnal Sain Veteriner*, 24(2):177-184.
- Otter A, Gamble L, Mazeri S, Handel IG, Bronsvooort BMDeC, Mellanby RJ, Meunier NV. 2018. Investigation of short-term surgical complications in a low-resource, high-volume dog sterilisation clinic in India. *BMC Veterinary Research*, 14 (56):1-8.
- Porters N, Polis I, Moons C, Duchateau L, Goethals K, Huyghe S, Rooster HD. 2014. Prepubertal gonadectomy in cats: different surgical techniques and comparison with gonadectomy at traditional age. *Veterinary Record*, 175(9):1-5.
- Rahmiati DU, Wira DW. 2019. Induksi anestesi menggunakan Ket-A-Xyl® pada kucing domestik. *ARSHI Veterinary Letter*, 3(3):53-54.
- Redondo JI, Suesta P, Gil L, Soler G, Serra I, Soler C. 2012. Retrospective study of the prevalence of postanaesthetic hypothermia in cats. *Veterinary Record*, 170(8):206-206.
- Rubio M, Katiuska S, Jose MC, Angel HG, Belen C, Deborah C, Elena, Ayla DR, Joaquin S. 2022. Changes in hematological and biochemical profiles in ovariohysterectomized bitches using an alfaxalone-midazolam-morphine-sevoflurane protocol. *Animall*. 12(914):1-12.
- Shelby AM, McKune CM. 2014. *Small Animal Anesthesia Technique*. Wiley Blackwell, USA.
- Teixeira FA, Queiroz MR, Oba PM, Olivindo RFG, Ernandes MC, Duarte CN, Rentas MF, Brunetto MA. 2020. Brazilian owners perception of the body condition score of dogs and cats. *BMC Veterinary Research*, 16(463):1-9.
- Thomas JA, Lerche P. 2017. *Anesthesia and Analgesia for Veterinary Technicians*. Elsevier, Canada.
- Thrall D, Robertson I. 2015. *Atlas of Normal Radiographic Anatomy and Anatomic Variants in the Dog and Cat*. Elsevier Saunders. St. Louis, Missouri.
- Vester BM, Sutter SM, Keel TL, Graves TK, Swanson KS. 2009. Ovariohysterectomy alters body composition and adipose and skeletal muscle gene expression in cats fed a high-protein or moderate-protein diet. *Animal*, 3(9):1287-1298.
- Zlateva N, Marinov G. 2015. Effect of three anesthetic protocols on the hematological indices in cats during ovariohysterectomy. *MedInform*, 2(1):184-193.